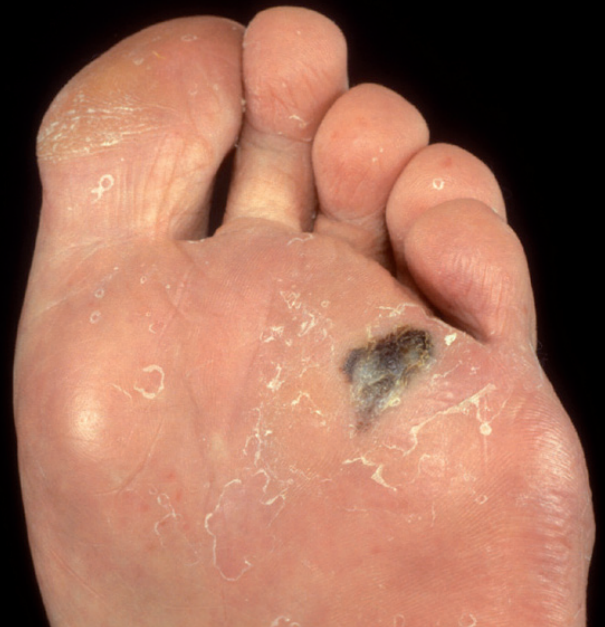


Don't gamble with melanoma



Coloured marks

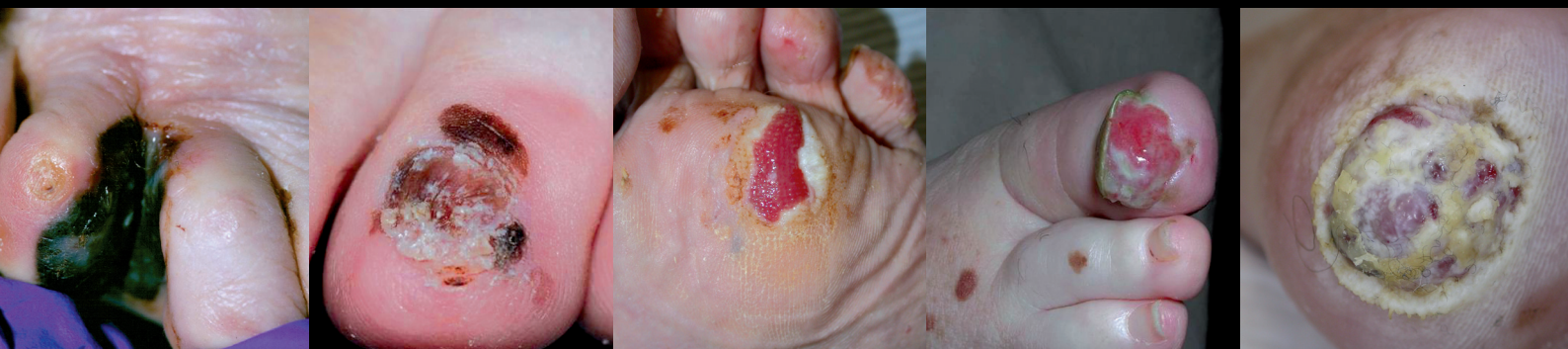Uncertain diagnosis

Bleeding, oozing or hypergranulation

Enlargement

Delay in healing - more than 2 months

Refer when any two or more apply¹



¹Bristow IR, de Berker DAR, Acland K et al. *Clinical guidelines for the recognition of melanoma of the foot and nail unit*. Journal of Foot and Ankle Research 2010, 3:25.
Available from: <http://www.jfootankleres.com/content/3/1/25>