

# RETINA The Journal of Retinal and Vitreous Diseases

## Vitreomacular traction affects anti-Vascular Endothelial Growth Factor treatment outcomes for Exudative Age-related macular degeneration --Manuscript Draft--

<b>Manuscript Number:</b>	Retina 214-0872R2
<b>Full Title:</b>	Vitreomacular traction affects anti-Vascular Endothelial Growth Factor treatment outcomes for Exudative Age-related macular degeneration
<b>Short Title:</b>	VMT affecting treatment in wet AMD
<b>Article Type:</b>	Original Study
<b>Keywords:</b>	age-related macular degeneration; anti-vascular endothelial growth factor; exudative; vitreomacular traction
<b>Corresponding Author:</b>	Radhika Krishnan, FRCOphth University Hospital Southampton Southampton, UNITED KINGDOM
<b>Corresponding Author Secondary Information:</b>	
<b>Corresponding Author's Institution:</b>	University Hospital Southampton
<b>Corresponding Author's Secondary Institution:</b>	
<b>First Author:</b>	Radhika Krishnan, FRCOphth
<b>First Author Secondary Information:</b>	
<b>Order of Authors:</b>	Radhika Krishnan, FRCOphth
	Rashi Arora, MRCOphth
	Gabriella De Salvo, MD
	Alina Stinghe, MBBS
	Philip Severn, FRCOphth
	Bishwanath Pal, FRCOphth
	Srinivas Goverdhan, PhD
<b>Order of Authors Secondary Information:</b>	
<b>Manuscript Region of Origin:</b>	UNITED KINGDOM
<b>Abstract:</b>	<p><b>Purpose:</b> To evaluate the effect of vitreomacular traction (VMT) on the visual acuity outcomes and central retinal thickness measurements following intravitreal anti-vascular endothelial growth factor (anti-VEGF) therapy for the treatment of exudative AMD.</p> <p><b>Methods:</b> In this retrospective series, we evaluate the clinical records and optical coherence tomography (OCT) scans of 34 eyes of 32 patients, with VMT confirmed on OCT scanning at baseline, to assess the effects of VMT on anti-VEGF therapy for newly diagnosed exudative wet AMD. Best corrected visual acuity (BCVA) at baseline, 1, 3, 6, 9 and 12 months and central retinal thickness (CRT) at baseline, 3, 6, and 12 months were assessed. Comparison was made with a control group of 29 eyes of 28 patients with wet AMD and no VMT on OCT and with key variable dosing studies for anti-VEGF in exudative AMD (CATT, HARBOR, PrONTO, SUSTAIN and Gupta et al).</p> <p><b>Results:</b> BCVA results showed a visual acuity improvement that peaked at 3 months with 2.47 letters, well below other variable dosing studies for anti-VEGF therapy in exudative AMD. This was then followed by a steady decline with mean BCVA at 12 months ending below the baseline level (-1.00 letters) compared to a gain of 9.39 letters in the control group at 12 months. Comparison of the mean CRT in the VMT</p>

	<p>group between baseline and 12 months showed no significant difference (<math>P=0.67</math>), while the PrONTO study and control group showed a highly significant difference at 12 months compared to baseline (<math>P&lt; 0.001</math>). Mean CRT values at 6 and 12 months were essentially at baseline levels (0.26 <math>\mu\text{m}</math>, -0.62 <math>\mu\text{m}</math> respectively).</p> <p>Conclusion: VMT at baseline, existing concurrently with newly diagnosed exudative AMD treated with intravitreal anti-VEGF therapy on a variable dosing regime, was associated with poorer visual outcomes and a decreased response to reduction in CRT, compared to a control group of wet AMD without VMT treated with intravitreal anti-VEGF and compared to major variable dosing studies for intravitreal anti-VEGF in exudative AMD.</p>
<b>Suggested Reviewers:</b>	<p>Andrew Lotery, PhD  Professor and Consultant Ophthalmologist, University Hospital Southampton  A.J.Lotery@soton.ac.uk  Professor Lotery has published extensively in the field of Medical Retina and age-related macular degeneration</p>
<b>Opposed Reviewers:</b>	
<b>Response to Reviewers:</b>	<p>Reviewer Comments:</p> <p>While change in letter score is fine, the visual acuities should be provided with their Snellen equivalents. This needs to be done in Table 1. Otherwise the manuscript should be accepted.</p> <p>Amendments:</p> <p>I have added the Snellen equivalents to the ETDRS visual acuities in Table 1 as requested above.</p>

**Title:**

**Vitreomacular traction affects anti-Vascular Endothelial Growth Factor  
treatment outcomes for Exudative Age-related macular degeneration**

**Short title:**

VMT affecting treatment outcomes in wet AMD

R Krishnan FRCOphth<sup>1,2</sup>, R Arora MRCOphth<sup>1</sup>, G De Salvo MD<sup>1</sup>, A Stinghe  
MBBS<sup>1</sup>, P S Severn FRCOphth<sup>2</sup>, B Pal FRCOphth<sup>2</sup>, S Goverdhan PhD<sup>1</sup>

<sup>1</sup> Southampton Eye Unit, University Hospital Southampton, Southampton, UK  
<sup>2</sup> Moorfields Eye Hospital, City Road, London, UK

**Corresponding author:**

Miss R. Krishnan  
Southampton Eye Unit  
University Hospital Southampton  
Tremona road  
Southampton SO16 6YD  
E-mail: Radhika.Krishnan@uhs.nhs.uk

All authors would like to declare that we have no proprietary or competing  
interests regarding this report.

**Key words:**

Age-related macular degeneration; anti-vascular endothelial growth factor;  
exudative; vitreomacular traction

**Summary statement:**

In patients with AMD treated with anti-VEGF therapy on a variable dosing regime, concurrent vitreomacular traction was associated with a less favourable visual outcome and less of a reduction in central retinal thickness compared to a control group of treated wet AMD without VMT and compared to the major variable dosing regime studies of exudative AMD treated with anti-VEGF therapy

**Abstract:**

**Purpose:** To evaluate the effect of vitreomacular traction (VMT) on the visual acuity outcomes and central retinal thickness measurements following intravitreal anti-vascular endothelial growth factor (anti-VEGF) therapy for the treatment of exudative AMD.

**Methods:** In this retrospective series, we evaluate the clinical records and optical coherence tomography (OCT) scans of 34 eyes of 32 patients, with VMT confirmed on OCT scanning at baseline, to assess the effects of VMT on anti-VEGF therapy for newly diagnosed exudative wet AMD. Best corrected visual acuity (BCVA) at baseline, 1, 3, 6, 9 and 12 months and central retinal thickness (CRT) at baseline, 3, 6, and 12 months were assessed. Comparison was made with a control group of 29 eyes of 28 patients with wet AMD and no VMT on OCT and with key variable dosing studies for anti-VEGF in exudative AMD (CATT, HARBOR, PrONTO, SUSTAIN and Gupta et al).

**Results:** BCVA results showed a visual acuity improvement that peaked at 3 months with 2.47 letters, well below other variable dosing studies for anti-VEGF therapy in exudative AMD. This was then followed by a steady decline with mean BCVA at 12 months ending below the baseline level (-1.00 letters) compared to a gain of 9.39 letters in the control group at 12 months.

Comparison of the mean CRT in the VMT group between baseline and 12 months showed no significant difference ( $P=0.67$ ), while the PrONTO study and control group showed a highly significant difference at 12 months

1 compared to baseline ( $P < 0.001$ ). Mean CRT values at 6 and 12 months were  
2 essentially at baseline levels (0.26  $\mu\text{m}$ , -0.62  $\mu\text{m}$  respectively).  
3  
4  
5  
6

7 **Conclusion:** VMT at baseline, existing concurrently with newly diagnosed  
8 exudative AMD treated with intravitreal anti-VEGF therapy on a variable  
9 dosing regime, was associated with poorer visual outcomes and a decreased  
10 response to reduction in CRT, compared to a control group of wet AMD  
11 without VMT and compared to major variable dosing studies for intravitreal  
12 anti-VEGF in exudative AMD.  
13  
14  
15  
16  
17  
18  
19  
20  
21  
22  
23  
24  
25  
26  
27  
28  
29  
30  
31  
32  
33  
34  
35  
36  
37  
38  
39  
40  
41  
42  
43  
44  
45  
46  
47  
48  
49  
50  
51  
52  
53  
54  
55  
56  
57  
58  
59  
60  
61  
62  
63  
64  
65

## Introduction

Anti-vascular endothelial growth factor (anti-VEGF) treatments are effective for majority of patients with neovascular or wet age-related macular degeneration (AMD). Large randomized controlled trials have showed the benefit of Ranibizumab, Bevacizumab and Aflibercept in successfully treating choroidal neovascularisation (CNV) in wet AMD.<sup>1-4</sup> However, sub-optimal or non-responders remain a challenge as the reasons for this are multi-factorial with limited treatment options.<sup>5</sup> The vitreomacular interface may have a role in the response to anti-VEGF treatment. Vitreomacular adhesion (VMA) is defined as perifoveal vitreous separation with remaining vitreomacular attachment and undisturbed foveal features on ocular coherence tomography (OCT) scanning.<sup>6</sup> Vitreomacular traction (VMT) is defined as posterior vitreous detachment with remaining vitreomacular attachment causing anatomic distortion of the fovea.<sup>6</sup> Emerging evidence suggests that VMA and VMT can adversely affect the prognosis of AMD<sup>7,8</sup> and visual outcomes following anti-VEGF therapy for wet AMD.<sup>9</sup>

Although the exact pathogenesis of AMD remains unclear it is known that the CNV lesion predominantly affects the outer retina and retinal pigment epithelium (RPE), and that genetic factors can influence its development and response to treatment<sup>10-13</sup> It is possible that the vitreous contributes to the initial pathogenesis or progression of AMD as a number of studies show a higher incidence of posterior vitreous attachment in AMD (both for exudative and non-exudative AMD eyes) compared to age-matched control eyes.<sup>7-8, 14</sup>

1 Small studies suggest that patients with wet AMD and concurrent VMA may  
2 not respond as expected to anti-VEGF therapy.<sup>9,15,16</sup> This reduced response  
3 to treatment has been attributed to chronic tractional mechanical forces or  
4 induced inflammation from the traction.<sup>7-9,16</sup> Another study has looked at VMA  
5 in association with CNV and polypoidal choroidal vasculopathy (PCV) and did  
6 not find a difference in visual outcomes.<sup>17</sup> Filloy et al<sup>18</sup> in a European study,  
7 compared the responses to ranibizumab for wet AMD with VMT (n=18) with a  
8 control group of ranibizumab for wet AMD without VMT and found that  
9 patients with accompanying VMT showed a tendency to have poorer visual  
10 outcomes. In addition, a higher number of intravitreal injections were required  
11 in the VMT group compared to the control group.  
12  
13  
14  
15  
16  
17  
18  
19  
20  
21  
22  
23  
24  
25  
26  
27  
28

29 The purpose of this study is to assess the treatment responses to anti-VEGF  
30 therapy in wet AMD eyes with co-existing VMT pathology in a larger  
31 consecutive series. We assessed the outcomes of patients with VMT  
32 associated with CNV (secondary to AMD) treated with anti-VEGF therapy  
33 employing a variable dosing or pro re nata (PRN) regime. We compared the  
34 outcomes of these wet AMD patients with co-existent VMT treated with PRN  
35 anti-VEGF therapy to a control group without VMT on OCT treated with anti-  
36 VEGF therapy in the same eye unit as the VMT patients with the same PRN  
37 dosing regime. We also compared to the standard outcomes of wet AMD  
38 patients treated with similar PRN dosing regimes in large published studies.  
39  
40  
41  
42  
43  
44  
45  
46  
47  
48  
49  
50  
51  
52  
53  
54  
55  
56  
57  
58  
59  
60  
61  
62  
63  
64  
65



## Methods

This is a retrospective study of consecutive patients undergoing PRN treatment for CNV in AMD with co-existing VMT (defined as posterior vitreous detachment with remaining vitreomacular attachment causing anatomic distortion of the fovea.<sup>6</sup>) detected by spectral-domain optical coherence tomography (SD-OCT) at baseline (3D OCT-2000 Spectral Domain OCT, Topcon). This study followed the tenets of the declaration of Helsinki. Patients were identified using hospital databases in 2 centres, University Hospital Southampton and Moorfields Eye Hospital and data collated from patients' clinical records. The PRN regime was consistent across both centres and consisted of 3 loading doses of anti-VEGF therapy for all new patients, 4 weeks apart, following by injections if there were signs of new or increasing subretinal fluid (SRF) or intraretinal fluid (IRF), new haemorrhage or reduced vision of  $\geq 5$  letters associated with SRF or IRF. If no injection was given patients were reviewed at approximately 4 weekly intervals.

A total of 34 eyes of 32 patients were evaluated with best-corrected visual acuity (BCVA) and central retinal thickness (CRT) assessed at 0, 3, 6, 9 and 12 months. Results were compared with our control group of 29 eyes of 28 patients without VMT treated with ranibizumab for CNV in AMD in the same eye unit as the VMT patients (University Hospital Southampton) with the same PRN dosing regime and with published data from CATT<sup>2</sup>, HARBOR<sup>19</sup>, PrONTO<sup>20</sup>, SUSTAIN<sup>21</sup> and Gupta et al<sup>22</sup> studies to compare treatment outcomes between our VMT group and those seen in these similar variable-dosing regimen studies.

Inclusion criteria used for the study were:

- a) Wet AMD identified by SD-OCT scanning and fundus fluorescein angiography (FFA) treated with intravitreal anti-VEGF therapy using Ranibizumab or Bevacizumab and VMT (defined as above)
- b) Follow-up for a minimum of 12 months.
- c) Availability of results from an SD-OCT at baseline, 3, 6, and 12 months.
- d) Availability of BCVA records at baseline, 1, 3, 6, 9 and 12 months. BCVA was measured using a LogMAR testing and converted to ETDRS letters for the purposes of analysis and comparison to other studies. Patients with co-existing pathologies such as vascular occlusions were excluded from this study, as were patients who underwent intraocular surgery during the period of the study including cataract or vitrectomy surgery. CNV due to other pathologies such as inflammatory causes were also excluded. The diagnosis of CNV in AMD was based on the interpretation of both SD-OCT and FFA. VMT was identified on tomographic scans as per the definition above. Patients with VMA only were not included in the study.

We compared the visual acuity outcomes and central retinal thickness (CRT) measurements of patients with exudative AMD associated with VMT with data from our control group of patients from CATT<sup>2</sup>, HARBOR<sup>19</sup>, PrONTO<sup>20</sup>, SUSTAIN<sup>21</sup> and Gupta et al<sup>22</sup> studies which adopted a similar PRN regime for exudative AMD. This illustrates how the demographics, baseline characteristics and outcomes in our VMT group differ compare to wet AMD patients who have not been selectively identified as having VMT at baseline.

Statistical analysis, comparisons and graphs were performed using GraphPad Prism software version 6.0 (Mac OS X, GraphPad Software, La Jolla California USA, [www.graphpad.com](http://www.graphpad.com)). Follow-up and baseline CRT in our study were compared using the paired student t test.  $P < 0.05$  was considered statistically significant.

## Results

The comparison between our study population with CNV secondary to AMD associated with VMT (UK VMT PRN), our control group of CNV secondary to AMD without VMT and the other studies is shown in table 1.

BCVA results showed that there was a visual acuity improvement peaking at 3 months of 2.47 letters followed by a steady decline. Mean visual acuity at 12 months ended below the baseline level (Figure 1), whereas in the control group the mean improvement in visual acuity peaks at 12 months with a mean gain of 9.39 letters (Figure 2).

Results were then compared against data from CATT<sup>2</sup>, HARBOR<sup>19</sup>, PrONTO<sup>20</sup>, SUSTAIN<sup>21</sup> and Gupta et al<sup>22</sup> to evaluate outcomes of the VMT group in our study and the response to treatment of CNV secondary to AMD along side other variable-dosing regimen studies at the same time points. Mean baseline BCVA (ETDRS letters) was comparable between all groups at 55.7 (VMT group), 61.5 (CATT<sup>2</sup>), 54.5 (HARBOR<sup>19</sup>), 56.2 (PrONTO<sup>20</sup>), 56.1 (SUSTAIN<sup>21</sup>), and 44.48 (Gupta et al<sup>22</sup>). The mean number of anti-VEGF injections in the VMT group was 5.9 compared to 6.9 (CATT<sup>2</sup>), 7.7 (HARBOR<sup>19</sup>), 5.6 (PrONTO<sup>20</sup>), 5.6 (SUSTAIN<sup>21</sup>) and 4.5 (Gupta et al<sup>22</sup>). Mean change in BCVA showed a modest average improvement in vision, however this was well below that seen in the other studies. Furthermore at 12-months, the visual acuity was below the baseline in the VMT group. Mean change in BCVA at 3 months and 12 months was +2.47 and -1.00 (VMT group) when compared to +7.01 and +9.39 (control) +5.6 and +6.8 (CATT<sup>2</sup>), +10.6 and +9.30 (PrONTO<sup>20</sup>), +5.8 and +3.6 (SUSTAIN<sup>21</sup>), and +7.05 and +4.03 (Gupta et al<sup>22</sup>) respectively. Figure 3 shows a comparison of our study group (UK VMT PRN) with our control group and with the other studies mentioned, clearly illustrating the difference in treatment response and overall poor outcome at the end of the 12-month period.

Comparison of the mean CRT in the VMT group between baseline and 12 months showed no significant difference ( $P=0.67$ ), while the control group (figure 4) and the PrONTO<sup>20</sup> study group showed a highly significant difference at 12 months compared to baseline ( $P< 0.001$ ). Figure 5 illustrates that the VMT group data shows a slight reduction in CRT at 3 months but average CRT values at 6 and 12 months revert back to near baseline levels.

## Discussion

This study of wet AMD patients having concurrent vitreomacular traction (VMT) being treated with anti-VEGF therapy showed a poorer visual outcome in these patients including a marked difference compared to a control group without VMT on OCT treated with ranibizumab for CNV in AMD with the same PRN dosing regime. The central retinal thickness (CRT) showed no significant reduction when compared to baseline at 12 months. The poorer visual outcome was noted at all time points studied with the greatest difference at the 12-month point when the average visual acuity was below the baseline level in the VMT group. This was mirrored by less of a reduction in mean CRT with anti-VEGF therapy with a small reduction in mean CRT at 3 months only followed by a return of the mean CRT at 6 and 12 months essentially back to baseline. There was no significant change at 12 months compared to baseline in the VMT group compared to a statistically significant reduction in CRT at 12 months in the control group and the PrONTO<sup>20</sup> study.

A number of studies have postulated that vitreous traction can have a deleterious effect on the treatment response of anti-VEGF therapy for wet

AMD.<sup>7-8,16</sup> It has also been suggested that the presence of VMT can be correlated with the severity of wet AMD<sup>16</sup>. Theories linking VMT and the poorer response to anti-VEGF treatment in this group include chronic inflammation and mechanical tractional forces as discussed previously. Some reports have identified an abnormally strong attachment at the macula in patients with wet AMD.<sup>23</sup> It has also been shown that vitrectomy to detach the posterior vitreous cortex could improve CNV regression.<sup>24</sup> In 2 reported cases of vitrectomy for post-injection endophthalmitis, this lead to sustained regression of the CNV. It was postulated that detachment and removal of the posterior vitreous cortex contributed to the regression.<sup>25</sup>

Hence this group of patients, who are unlikely to show the same treatment response to anti-VEGF therapy alone, may benefit from alternative treatment options such as earlier vitrectomy in combination with anti-VEGF therapy.

Mojana et al<sup>16</sup> reported an improvement in visual acuity after 25-gauge pars plana vitrectomy with removal of posterior vitreous cortex in five patients who had a history of demonstrable VMA and poorly responsive choroidal neovascularisation (CNV) despite aggressive anti-VEGF therapy.

In contrast to other variable-dosing regime studies showing better outcomes, the presence of VMT often leads to poorer visual and anatomical outcomes during anti-VEGF therapy for wet AMD. Surgical intervention to address VMT is an option to be considered in managing this difficult group of patients when the expected response is not achieved. The successful use of pharmacologic vitreolysis<sup>26, 27</sup> to relieve symptomatic vitreomacular traction<sup>28, 29</sup> is an

interesting development that may also have uses in this group of patients and studies exploring this are underway. It is important to address the patient's expectations and perform adequate counselling prior to commencing treatment to inform this group of patients that the prognosis in cases of VMT associated with wet AMD treated with anti-VEGF treatment alone is likely to be less favourable.

## References

1. Heier JS et al. Intravitreal aflibercept (VEGF trap-eye) in wet age-related macular degeneration. *Ophthalmology* 2012; 119:2537-2548.
2. Martin DF et al. Ranibizumab and bevacizumab for neovascular age-related macular degeneration. *N Engl J Med* 2011; 364:1897-1908.
3. Avery RL et al. Intravitreal bevacizumab (Avastin) for neovascular age-related macular degeneration. *Ophthalmology* 2006; 113:363-372 e365.
4. Rosenfeld PJ et al. Ranibizumab for neovascular age-related macular degeneration. *N Engl J Med* 2006; 355:1419-1431.
5. Lux A et al. Non-responders to bevacizumab (Avastin) therapy of choroidal neovascular lesions. *Br J Ophthalmol* 2007; 91:1318-1322.
6. Duker JS, Kaiser PK, Binder S, de Smet MD, Gaudric A, Reichel E, Sadda SR, Sebag J, Spaide RF, Stalmans P. The International Vitreomacular Traction Study Group classification of vitreomacular adhesion, traction, and macular hole. *Ophthalmology*. 2013;120:2611-9.
7. Krebs I, et al.: Posterior vitreo-macular adhesion: a potential risk factor for exudative age-related macular degeneration. *Am J Ophthalmol* 144:741-746, 2007
8. Robison C, et al.: Vitreo-macular adhesion in active and end-stage age-related macular degeneration. *Am J Ophthalmol* 148:79-82, 2009
9. Lee SJ and Koh HJ. Effects of vitreomacular adhesion on anti-vascular endothelial growth factor treatment for exudative age-related macular degeneration. *Ophthalmology* 2011; 118:101-110.
10. Goverdhan SV et al. An analysis of the CFH Y402H genotype in AMD patients and controls from the UK, and response to PDT treatment. *Eye (Lond)* 2008; 22:849-854.
11. Brantley MA, Jr. et al. Association of complement factor H and LOC387715 genotypes with response of exudative age-related macular degeneration to photodynamic therapy. *Eye (Lond)* 2009; 23:626-631.
12. Klein RJ et al. Complement factor H polymorphism in age-related macular degeneration. *Science* 2005; 308:385-389.

13. Hagstrom SA et al. Pharmacogenetics for genes associated with age-related macular degeneration in the Comparison of AMD Treatments Trials (CATT). *Ophthalmology* 2013; 120:593-599.
14. Jackson TL et al. Vitreous attachment in age-related macular degeneration, diabetic macular edema, and retinal vein occlusion: a systematic review and metaanalysis. *Retina* 2013; 33:1099-1108.
15. Rotsos T et al. Intravitreal anti-VEGF treatment in eyes with combined choroidal neovascularisation and vitreomacular traction syndrome. *Br J Ophthalmol* 2010; 94:1205-1210.
16. Mojana F et al. The role of abnormal vitreomacular adhesion in age-related macular degeneration: spectral optical coherence tomography and surgical results. *Am J Ophthalmol* 2008; 146:218-227.
17. Cho HJ et al. Effects of vitreomacular adhesion on anti-vascular endothelial growth factor treatment for polypoidal choroidal vasculopathy. *Retina* 2013; 33:2126-2132.
18. Filloy A and Arias L. [Responses to ranibizumab in wet age-related macular degeneration patients with vitreomacular traction]. *Arch Soc Esp Oftalmol* 2013; 88:380-386.
19. Busbee BG et al. Twelve-month efficacy and safety of 0.5 mg or 2.0 mg ranibizumab in patients with subfoveal neovascular age-related macular degeneration. *Ophthalmology* 2013; 120:1046-1056.
20. Fung AE et al. An optical coherence tomography-guided, variable dosing regimen with intravitreal ranibizumab (Lucentis) for neovascular age-related macular degeneration. *Am J Ophthalmol* 2007; 143:566-583.
21. Holz FG et al. Safety and efficacy of a flexible dosing regimen of ranibizumab in neovascular age-related macular degeneration: the SUSTAIN study. *Ophthalmology* 2011; 118:663-671.
22. Gupta B et al. Comparison of two intravitreal ranibizumab treatment schedules for neovascular age-related macular degeneration. *Br J Ophthalmol* 2011; 95:386-390.
23. Schmidt JC et al. High incidence of vitreomacular traction in recurrent choroidal neovascularisation after repeated photodynamic therapy. *Br J Ophthalmol* 2006; 90:1361-1362.
24. Ikeda T et al. Pars plana vitrectomy for regression of choroidal neovascularization with age-related macular degeneration. *Acta Ophthalmol Scand* 2000; 78:460-464.
25. Emoto H, et al.: Regression of choroidal neovascularization following vitrectomy for post-injection endophthalmitis. *Retin Cases Brief Rep*. 2010;4:312-6.
26. Sebag J. Pharmacologic vitreolysis. *Retina*. 1998;18:1-3.
27. Sebag J. Pharmacologic vitreolysis--premise and promise of the first decade. *Retina*. 2009;29:871-4.
28. Stalmans P, Benz MS, Gandorfer A, Kampik A, Girach A, Pakola S, Haller JA; MIVI-TRUST Study Group. Enzymatic vitreolysis with ocriplasmin for vitreomacular traction and macular holes. *N Engl J Med*. 2012; 367: 606-15.
29. Syed YY, Dhillon S. Ocriplasmin: a review of its use in patients with symptomatic vitreomacular adhesion. *Drugs*. 2013; 73: 1617-25.



## Figure Legends

Table 1. Patient demographics and baseline characteristics from study cohorts (VMT and control) and published comparable AMD cohorts

Figure 1. Change in Mean Visual acuity at 1, 3, 6, 9 and 12 months compared to baseline in VMT group.

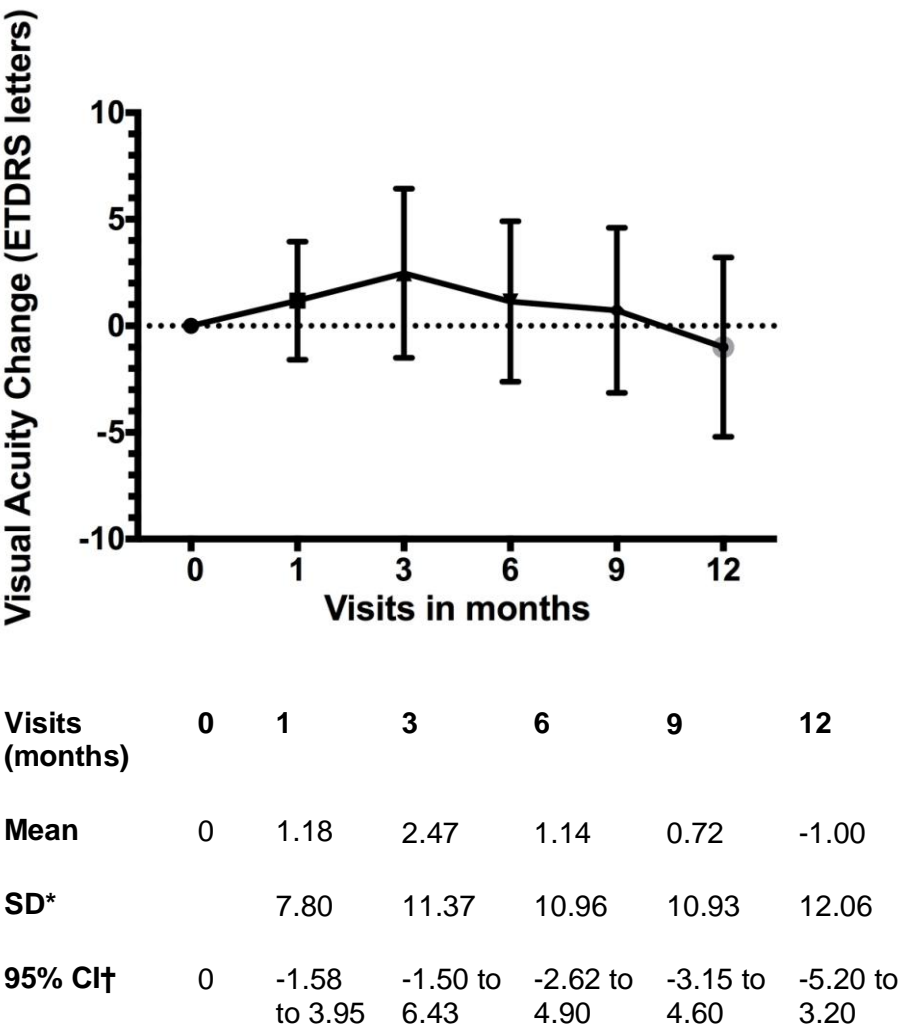
Figure 2. Change in Mean Visual acuity at 1, 3, 6, 9 and 12 months compared to baseline in control group.

Figure 3. Comparison of ETDRS visual acuity outcomes in UK VMT PRN group, control group and similar published PRN treated groups

Figure 4. Change in Mean Central Retinal Thickness at 3, 6 and 12 months compared to baseline in VMT group

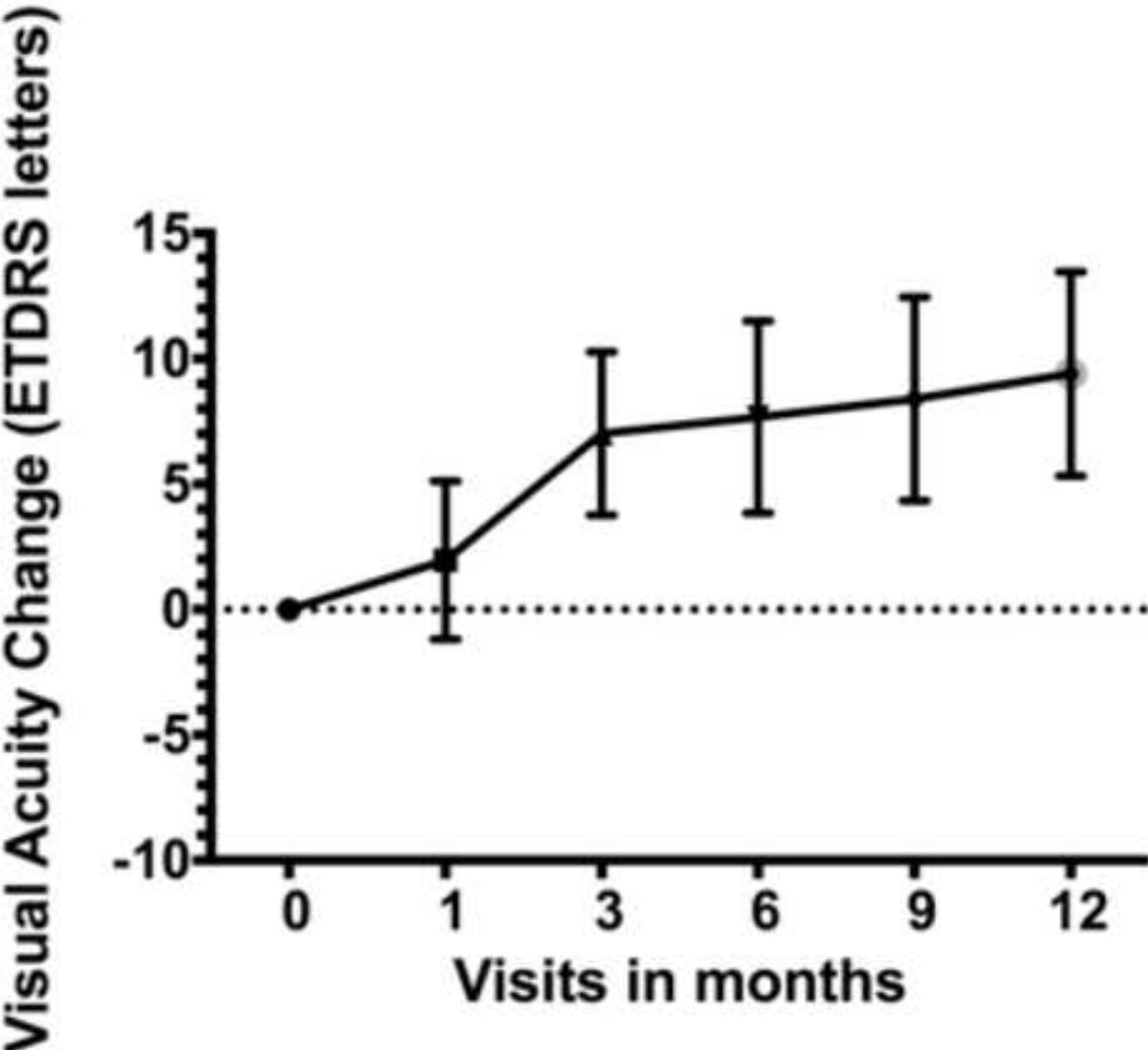
Figure 5. Change in Mean Central Retinal Thickness at 3, 6 and 12 months compared to baseline in control group

Figure 1



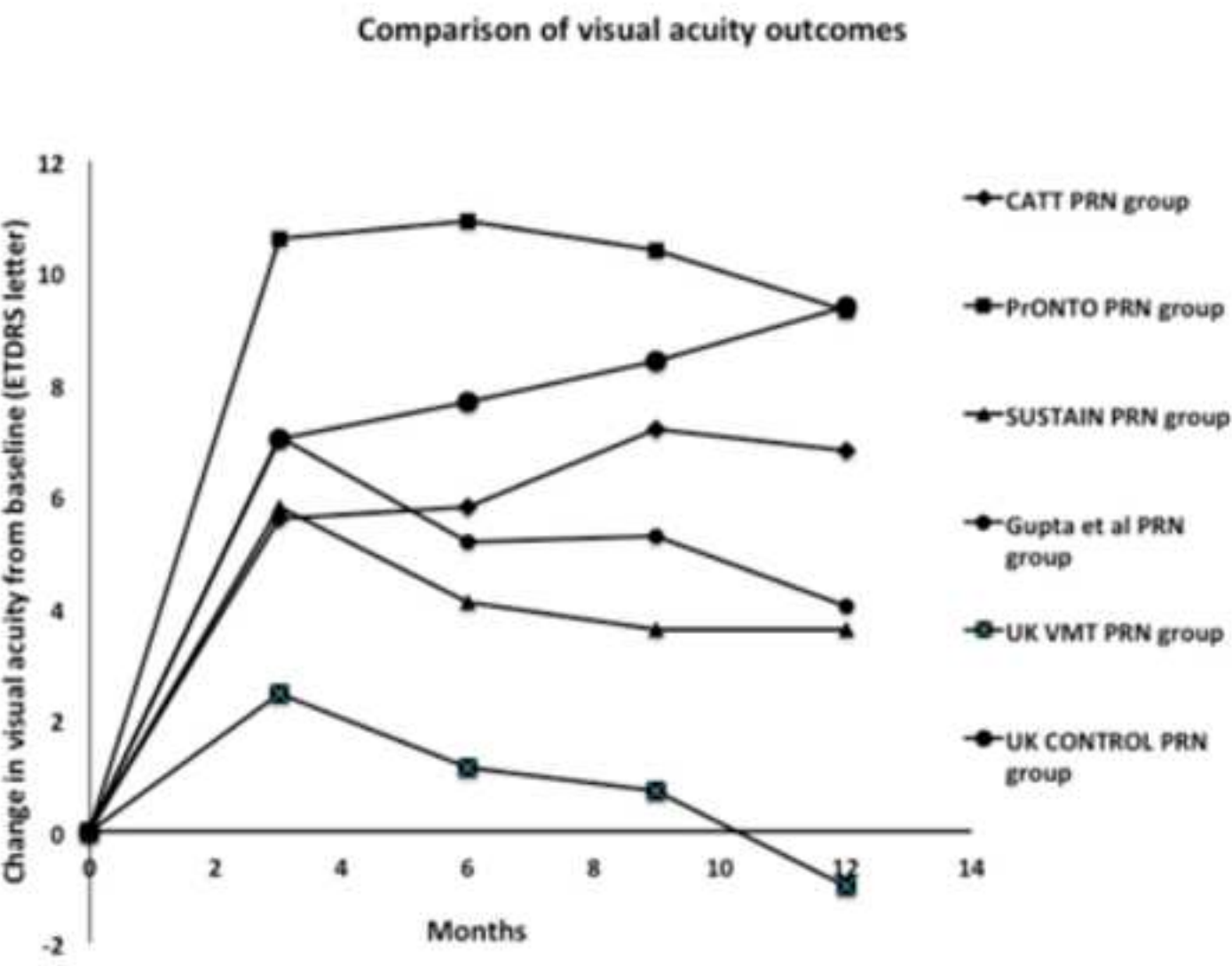
**Figure 1. Change in Mean Visual acuity at 1, 3, 6, 9 and 12 months compared to baseline**

(\*Standard Deviation, †Confidence Interval).



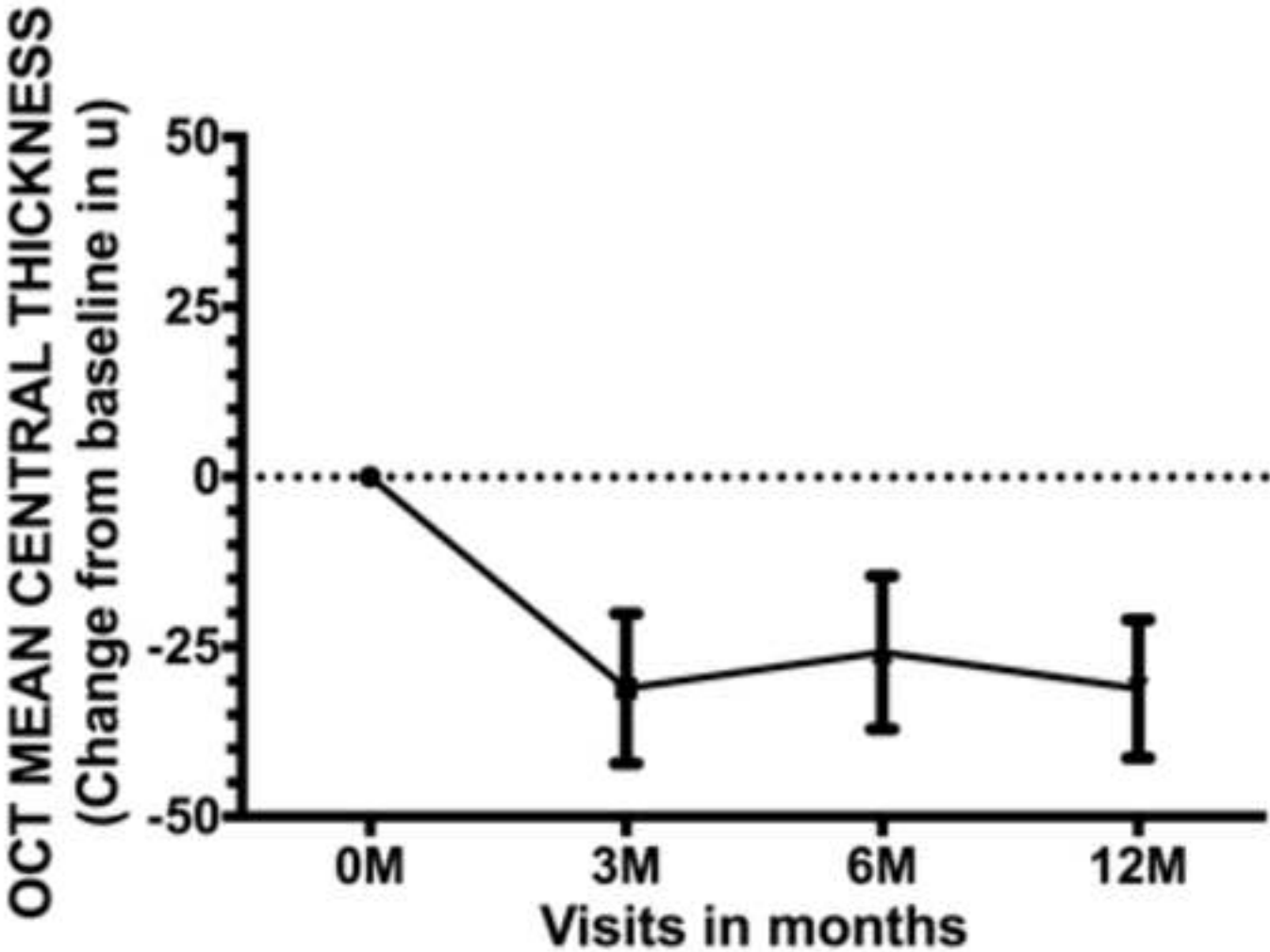
Visits (months)	0	1	3	6	9	12
Mean	0	1.97	7.01	7.67	8.39	9.39
SD*		8.29	8.55	10.07	10.68	10.69
95% CI†	0	-1.19 to 5.12	3.76 to 10.27	3.84 to 11.50	4.37 to 12.46	5.33 to 13.46

Figure 3  
Click here to download Figure (Please type in the figure number in the Description Box; Fig 1, Fig 2, etc.): figure 3 updated with controls. F



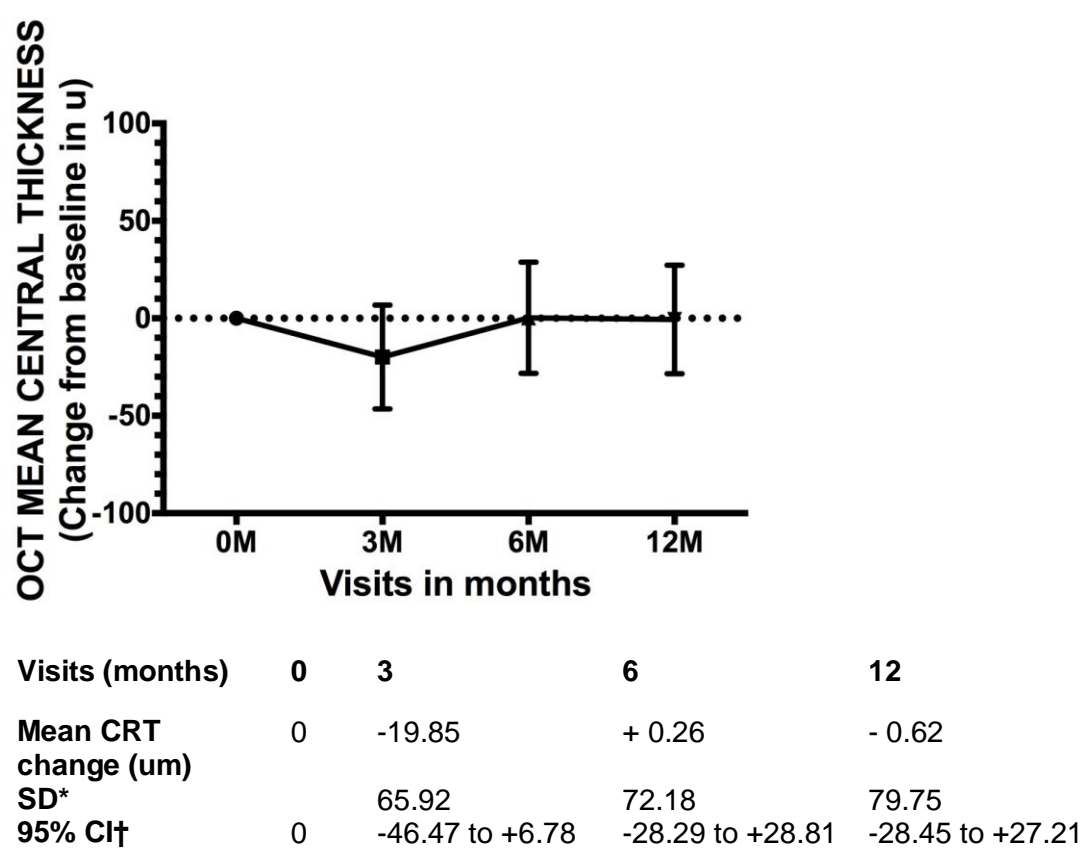
Mean ETDRS letter change	0	3 months	6 months	9 months	12months
CATT PRN	0	5.60	5.80	7.20	6.80
PrONTO PRN	0	10.60	10.90	10.40	9.30
SUSTAIN PRN	0	5.80	4.10	3.60	3.60
Gupta et al PRN	0	7.05	5.16	5.26	4.03
UK VMT PRN	0	2.47	1.14	0.72	-1.0
UK Control PRN	0	7.01	7.67	8.39	9.39

Figure 4  
[Click here to download Figure \(Please type in the figure number in the Description Box; Fig 1, Fig 2, etc.\): figure 4 OCT controls.tiff](#)



Visits (months)	0	3	6	12
Mean CRT change (um)	0	-31.14	-25.83	- 31.17
SD*		29.04	29.61	26.75
95% CI†	0	-42.18 to -20.09	-37.09 to -14.56	-41.35 to -21.0

Figure 5



**Figure 3. Change in Mean Central Retinal Thickness at 3, 6 and 12 months compared to baseline**

(\*Standard Deviation, †Confidence Interval).

Table 1

	UK VMT PRN group, n = 34	UK control Ranibizumab PRN n=29	CATT <sup>2</sup> Ranibizumab PRN n = 298	HARBOR <sup>16</sup> Ranibizumab PRN n = 275	PrONTO <sup>17</sup> Ranibizumab PRN n = 40	SUSTAIN <sup>18</sup> Ranibizumab PRN, n = 513	Gupta et al <sup>19</sup> PRN n = 31
<b>Age (years)</b> Mean ± SD Range	79.31 ± 6.47 64 - 90	83.03 ± 5.43 66 - 90	78.4± 7.8 50-90	78.5± 8.3 53.0–97.0	83.5 ± 7.2 69 -100	75.1 ±8.06 39–93	81.9±5.99 75-90
<b>Sex, n</b> Male Female	M=8 F= 24	M=14 F=14	M=113 F=185	M=112 F=163	M=14 F=26	M= 219 F= 294	M=12 F=19
<b>Ethnicity, n</b> White	28	28	296	268	40	508	-
<b>CNV lesion type</b> Classic PC Minimally Classic Occult Fibrovascular PED <sup>†</sup> (occult) Serous PED <sup>†</sup> (occult) RAP <sup>‡</sup> lesions	1 6 2 21 5 - - -	1 1 0 12 13 2 0	- - - - - - -	- 47 128 100 - - -	- 7 23 10 - 10 -	- 78 88 129 216 - -	- 16%(5) - 32%(10) 51%(15) - -
<b>Baseline VA</b> Mean ETDRS letters (Snellen equivalent) ± SD Range (ETDRS letters)	55.68 (6/24) ±11.87 25 (5/60) – 76 (6/9)	55.97 (6/24) ±13.36 28.5 (5/60) – 79 (6/9)	61.5 (6/18) ±13.2	54.5 (6/24) ±11.7 26 (5/60) – 73 (6/12)	56.0 (6/24)	56.1 (6/24) ±12.19	44.48 (6/36) ±15.41
<b>Baseline CRT (microns)</b> Mean ± SD Range	286.4±54.6 178-372	281.5±32.7 235-371	294±139	347.8±143.8	394	340.5 ±113.2 128–1029	-
<b>Mean Follow up</b> Months ± SD	12	12	12*	12	12*	12	12
<b>Mean Injections</b> Injections/year ± SD	5.85 ± 2.41	6.9 ± 2.5	6.9±3.0*	7.7	5.6 ± 2.3	5.6	4.5

Table 1. Patient demographics and baseline characteristics from study cohort and published comparable AMD cohorts<sup>2,16,17,18,19</sup>

(- Data not available, \*12 months data used, <sup>†</sup>Pigment epithelial detachment, <sup>‡</sup> Retinal angiomatous proliferation, PC=Predominantly Classic).



[Click here to download Copyright Transfer Form: Copyright form RETINA page 1.jpg](#)

[Click here to download Copyright Transfer Form: Copyright form RETINA page2.jpg](#)

[Click here to download Copyright Transfer Form: Copyright form RETINA page 3.jpg](#)

[Click here to download Copyright Transfer Form: Copyright form RETINA page4.jpg](#)

[Click here to download Copyright Transfer Form: 214-0872 Alina Copyright.tif](#)

[Click here to download Copyright Transfer Form: 214-0872 Copyright Bish.pdf](#)

[Click here to download Copyright Transfer Form: 214-0872 Copyright Philip \(1\).JPG](#)