

Progressive myoclonic epilepsy with Fanconi syndrome

Eleanor G Seaby¹, Rodney D Gilbert^{2,3}, Reuben J Pengelly¹, Gaia Andreoletti¹,
Antonia Clarke⁴ and Sarah Ennis¹

¹Human Genetics and Genomic Medicine, Faculty of Medicine, University of Southampton, Southampton General Hospital, Southampton SO16 6YD, UK

²Wessex Regional Paediatric Nephro-Urology Service, Southampton Children's Hospital, Southampton SO16 6YD, UK

³Faculty of Medicine, University of Southampton, Southampton SO16 6YD, UK

⁴Department of Paediatric Neurology, St George's Hospital, London SW17 0QT, UK

Corresponding author: Rodney D Gilbert. Email: Rodney.Gilbert@uhs.nhs.uk

Lesson

This report illustrates the difficulties in diagnosing complex cases and demonstrates how whole exome sequencing can resolve complex phenotypes.

Keywords

Progressive myoclonic epilepsy, valproate, Fanconi syndrome, next generation sequencing, exome, *KCTD7*

Introduction

Myoclonic epilepsy and developmental regression are notoriously heterogeneous disorders, with a multitude of possible aetiologies. Whole exome sequencing is proving capable of facilitating the discovery of novel causal mutations for rare Mendelian disease of unknown aetiology.^{1,2} We discuss the application of whole exome sequencing in a case of severe myoclonic epilepsy and Fanconi syndrome and elucidate the features of a complex phenotype.

Patient presentation

An eight-year-old Pakistani boy (Figure 1) with history of myoclonic status epilepticus, myopathy, hypotonia, weakness and severe physical disability presented to nephrology following four weeks of pyrexia of unknown origin refractory to multiple antibiotics, deranged inflammatory markers and electrolyte disturbances.

Born at term with normal development during infancy, he took his first independent steps at 12 months but was unsteady with frequent falls. At 13 months, he developed head shaking, eyelid flickering and tremors of the hands and legs. At 22 months, he developed atonic drop attacks preceded by myoclonic

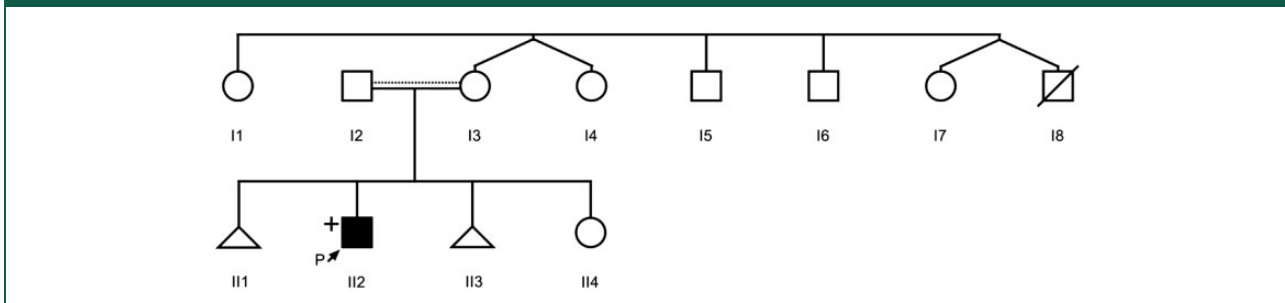
jerks of his right arm. An electro-encephalogram showed very high-amplitude slow wave activity and he received oral prednisolone with seizure resolution and improvement in his gait. Steroid therapy was weaned, and sodium valproate was introduced. Aged three, two episodes of non-convulsive status epilepticus preceded rapid developmental regression leaving our patient non-ambulant, hypotonic, aphasic and aphagic and requiring gastrostomy feeds. He had a marked myopathic facies and choreiform movements of the right arm. Medications trialled included ethosuximide, clobazam, acetazolamide, levetiracetam, topiramate, zonisamide, stiripentol and pulsed steroids without any enduring benefit. His parents reported consanguinity but did not disclose their degree of relatedness. His maternal uncle died from Leigh syndrome aged eight.

On admission, he was systemically unwell and febrile with no focus of infection. He had raised inflammatory markers; hypokalaemia; hypophosphataemia; heavy proteinuria primarily of tubular origin, with a markedly elevated urinary β 2-microglobulin and only modestly elevated urine albumin/creatinine ratio; normal anion gap metabolic acidosis; leucocytosis; and a normocytic anaemia. He was diagnosed with Fanconi syndrome and received electrolyte replacement therapy.

Investigations

A repeat electroencephalogram was highly abnormal with continuous spike activity maximum in the left centrotemporal and central areas. Magnetic resonance imaging of the brain showed generalised cerebral and cerebellar atrophy. Cerebrospinal fluid

Figure 1. Pedigree of the proband. Individuals I2 and I3 report to be related; however, the degree of relatedness is unknown. Individual I8 died at eight years from Leigh syndrome. III1 and III3 were miscarried at seven weeks. Affected individual shaded in black. '+' denotes individual whose exome was sequenced. Dotted line denotes implied consanguinity based upon low level of percentage heterozygosity present in the proband.



studies were normal. A muscle biopsy did not show any morphological or enzyme-based evidence of mitochondrial myopathy. Activity of electron transport chain complexes I-V was within normal limits. Testing for mitochondrial DNA depletion showed an intermediate result of 44% of mean normal levels. Whole gene sequencing revealed no mutations in *POLG*, and mitochondrial DNA analysis was negative for mutations m3243A > G and m8344A > G. This patient was a candidate for whole exome sequencing and genomic DNA was extracted and analysed.

Data analysis

In total, 24,543 variants were called. Low-percentage heterozygosity in the proband indicated parental consanguinity. Initial analysis was targeted towards nuclear-encoded mitochondrial genes with no rare recessive mutations found, but pan-exomic interrogation identified a rare homozygous missense variant in *KCTD7* (c.332C > A; pLeu108Met), previously described in Pakistani siblings from consanguineous parents with a near-identical phenotype (Table 1).³ The mutation was confirmed heterozygous in the proband's parents.

Discussion

The potassium channel tetramerization domain containing 7 (*KCTD7*) gene is highly expressed in the brain.³ Recessive mutations in *KCTD7* have been associated with progressive myoclonic epilepsy type 3 (PME), a severe neurodegenerative disease characterised by myoclonic seizures and developmental regression.³⁻⁵ Although the Leu108Met mutation explains many features of our patient's phenotype, it does not explain his Fanconi syndrome nor pyrexia of unknown origin. Fanconi syndrome was therefore attributed to valproate therapy.

Valproate-induced Fanconi syndrome (VIF)

Fanconi syndrome is a very rare complication of valproate therapy, yet reported cases are almost exclusively observed in severely disabled individuals, particularly those who are tube fed.^{6,7} There is frequently a prolonged lag period (up to 13 years)⁶ between drug initiation and onset of symptoms, which may deter clinicians from a valproate-induced Fanconi syndrome diagnosis. Furthermore, pyrexia of unknown origin has been reported as the initial presenting complaint in several cases of valproate-induced Fanconi syndrome,^{6,8} prompting the incidental diagnosis of Fanconi syndrome. Accurate identification of valproate-induced Fanconi syndrome is particularly pertinent since drug cessation has been shown to resolve Fanconi syndrome and pyrexia of unknown origin.^{6,8}

Lessons learnt

When presented with complex phenotypes, Occam's razor often prevails; the simplest diagnosis with the fewest assumptions is probably the correct one. For this patient, the five key phenotypic characteristics were:

1. Myoclonic epilepsy with weakness and hypotonia
2. Severe developmental disability
3. Fanconi syndrome
4. Pyrexia of unknown origin
5. Family history of Leigh syndrome

A mitochondrial disease was the preferred diagnosis that could explain the five features, and thus prompted muscle biopsy analysis and genetic studies. Initially, there was suggestion that Fanconi syndrome may have been secondary to valproate therapy; however, in view of: (a) a probable

Table 1. Rare homozygous variants.

Variant type	Gene	Exon	Transcript ID	Coding change	Protein change	PhyloP	GERP++	MAF
Non-synonymous_SNV	ABLIM1	exon14	NM_001003408	C1387T	R463W	0.99	5.42	.
Non-synonymous_SNV	ADD3	exon14	NM_019903	G1780A	V594I	0.99	5.54	.
Non-synonymous_SNV	CPEB2	exon1	NM_001177383	C931G	P311A	.	.	.
Non-synonymous_SNV	DMD	exon1	NM_004014	G3A	M1I	.	.	.
Non-synonymous_SNV	DUSP18	exon2	NM_152511	T167C	V56A	0.99	4.92	.
Stopgain_SNV	GPLD1	exon5	NM_001503	G418T	G140X	0.99	5.03	.
Frameshift_deletion	ICAIL	exon6	NM_138468	544_545del	182_182del	.	.	.
Non-synonymous_SNV	KCTD7	exon3	NM_001167961	C322A	L108M	0.92	2.77	.
Non-synonymous_SNV	MDM1	exon14	NM_017440	G2105T	R702L	0.99	5.11	.
Non-synonymous_SNV	MED1	exon11	NM_004774	A819C	L273F	0.97	2.71	.
Non-synonymous_SNV	PARD3B	exon20	NM_152526	G2910T	E970D	0.97	2.06	.
Non-synonymous_SNV	PKD1	exon19	NM_000296	C7502T	A2501V	0.98	2.31	.
Non-synonymous_SNV	SMARCA1	exon1	NM_139035	C92T	P31L	0.99	3.1	.
Non-synonymous_SNV	TBC1D10A	exon7	NM_031937	A749C	Q250P	0.99	4.12	.
Non-synonymous_SNV	TDRD6	exon1	NM_001168359	G308T	R103L	0.99	4.88	.

Note: Pan-exomic interrogation was targeted towards rare homozygous variants. Sixteen variants were prioritised on the following criteria: rejection of synonymous variants; minor allele frequency <0.01; PhyloP score (a measure of conservation) >0.9; GERP++ score positive; Logit score positive (a pathogenic prediction measure) for non-synonymous variants; Δ MaxEnt – Splicing variants scored above |2|. The row set in bold font identifies pathogenic candidate variant.

MAF: minor allele frequency (1000 genomes project); SNV: single nucleotide variant; Variant type: nature of variant.

mitochondrial disease; (b) the lag period before valproate-induced Fanconi syndrome manifested and (c) a pyrexia of unknown origin not at the time known to be linked to valproate-induced Fanconi syndrome, this was deemed unlikely and whole exome sequencing analysis was performed and targeted towards nuclear-encoded mitochondrial genes. Although interrogation of mitochondrial candidate genes was unsuccessful, whole exome sequencing facilitated a least-biased interrogation of the patient's entire exome enabling the identification of a causal mutation in *KCTD7*, which in turn enabled us to:

1. Recognise *KCTD7* as a cause of myoclonic epilepsy with severe developmental delay and myopathy
2. Exclude a mitochondrial disease
3. Reflect and reconsider the diagnosis of valproate-induced Fanconi syndrome
4. Initiate a change in therapy

This highlights the importance of considering drug reactions even if a patient has been on a drug for some time. Furthermore, this has enabled us to reflect on the provenance on his pyrexia at the time of his admission; perhaps this was a manifestation of valproate-induced Fanconi syndrome.

Although the discovery of the *KCTD7* mutation is unlikely to significantly change the outcome for our patient, giving his family a diagnosis can be incredibly valuable for them. Although our initial assumption of a mitochondrial disorder was incorrect, we applied available clinical information to interpret exomic data and determine the causal mutation responsible for the primary diagnosis of progressive myoclonic epilepsy type 3. This subsequently allowed us to re-evaluate our initial assumptions and explain the outstanding phenotypic characteristics not explained by the primary diagnosis.

Mutations of *KCTD7* should be considered in children who present with multifocal myoclonic seizures with or without generalised tonic clonic seizures

associated with psychomotor regression after normal development for the first 10 months to 3 years.

Declarations

Competing interests: None declared.

Funding: EGS was supported through the Wolfson intercalated awards programme and the University of Southampton Faculty of Medicine research project funding for students studying for a masters in medical science. Further financial support came from the Kerkut Charitable Trust and Alexion Pharma. The funders had no role in study design, data collection, data analysis, manuscript preparation or publication decisions.

Contributorship: EGS: exomic data analysis, clinical data review, initial draft manuscript, approval of final manuscript. RDG: clinical consultant, jointly conceived the project with Professor Ennis, reviewed and revised the manuscript, approved the final manuscript, supervision. RJP: bioinformatics supervision, reviewed the manuscript and approved the final manuscript. GA: bioinformatics quality control analysis and approved the final manuscript. AC: clinical consultant, supervision, approved the final manuscript. SE: jointly conceived the project with RDG, exomic analysis oversight, reviewed and revised the manuscript, supervision, approved the final manuscript.

Ethical approval: Written informed consent to publication was obtained from the patient's next of kin.

Guarantor: RDG.

Provenance: Not commissioned; peer-reviewed by Naveed Malek.

References

1. Bamshad MJ, Ng SB, Bigham AW, Tabor HK, Emond MJ, Nickerson DA, et al. Exome sequencing as a tool for Mendelian disease gene discovery. *Nat Rev Genet* 2011; 12: 745–755.
2. DePristo MA, Banks E, Poplin R, Garimella KV, Maguire JR, Hartl C, et al. A framework for variation discovery and genotyping using next-generation DNA sequencing data. *Nat Genet* 2011; 43: 491–498.
3. Lemke JR, Riesch E, Scheurenbrand T, Schubach M, Wilhelm C, Steiner I, et al. Targeted next generation sequencing as a diagnostic tool in epileptic disorders. *Epilepsia* 2012; 53: 1387–1398.
4. Kousi M, Anttila V, Schulz A, Calafato S, Jakkula E, Riesch E, et al. Novel mutations consolidate KCTD7 as a progressive myoclonus epilepsy gene. *J Med Genet* 2012; 49: 391–399.
5. Van Bogaert P, Azizieh R, Désir J, Aeby A, De Meirleir L, Laes JF, et al. Mutation of a potassium channel-related gene in progressive myoclonic epilepsy. *Ann Neurol* 2007; 61: 579–586.
6. Watanabe T, Yoshikawa H, Yamazaki S, Abe Y and Abe T. Secondary renal Fanconi syndrome caused by valproate therapy. *Pediatr Nephrol* 2005; 20: 814–817.
7. Balreira A, Gaspar P, Caiola D, Chaves J, Beirão I, Lima JL, et al. A nonsense mutation in the LIMP-2 gene associated with progressive myoclonic epilepsy and nephrotic syndrome. *Hum Mol Genet* 2008; 17: 2238–2243.
8. Nozaki F, Kumada T, Kusunoki T, Fujii T, Murayama K and Ohtake A. Fever of unknown origin as the initial manifestation of valproate-induced Fanconi syndrome. *Pediatr Neurol* 2014; 51: 846–849.