

Anatomical subgroup analysis of the MERIDIAN cohort: Posterior fossa abnormalities

Short title: iuMR for the posterior fossa abnormalities

Paul D Griffiths PhD FRCR¹, Karen Brackley FRCOG DM², Michael Bradburn MSc³,
Daniel JA Connolly BSC MRCP FRCR⁴, Mary L Gawne-Cain MRCP, FRCR, MD²,
Mark D Kilby DSc MD FRCOG, FRCPI⁵, Laura Mandefield MSc³, Cara Mooney
MSc³, Stephen C Robson MD MRCOG FRCP(Ed)⁶, Brigitte Vollmer MD, PhD⁷,
Gerald Mason MD FRCOG⁸

¹Academic Unit of Radiology, University of Sheffield, Glossop Road, Sheffield, S10 2JF, England ii) INSIGNEO Institute for in silico Medicine, University of Sheffield, UK, S10 2JF, ² University Hospital Southampton NHS Foundation Trust, UK SO16 6YD, ³Clinical Trials Research Unit, School of Health and Related Research, University of Sheffield, S1 4DA, ⁴Department of Radiology, Sheffield Children's Hospital, S10 2TH and the Royal Hallamshire Hospital, Sheffield Teaching Hospitals NHS Foundation Trust, S10 2JF, ⁵i) Centre for Women's & Newborn Health, Institute of Metabolism & Systems Research, University of Birmingham, B15 2TT. ii) Fetal Medicine Centre, Birmingham Women's Foundation Trust (Birmingham Health Partners), Birmingham, B15 2TG, ⁶Newcastle University, Newcastle upon Tyne NE2 4HH, ⁷Clinical and Experimental Sciences University of Southampton and Southampton Children's Hospital, University Hospital Southampton NHS Foundation Trust SO16 6YD ⁸Leeds Teaching Hospitals NHS trust, LS9 7TF

This article has been accepted for publication and undergone full peer review but has not been through the copyediting, typesetting, pagination and proofreading process, which may lead to differences between this version and the Version of Record. Please cite this article as doi: 10.1002/uog.17485

Corresponding author

Professor Paul Griffiths

Academic Unit of Radiology,

University of Sheffield,

Floor C, Royal Hallamshire Hospital

Glossop Road,

Sheffield, S10 2JF

England

Tel. +44 114 215 9604

Fax +44 114 271 1714

Email p.griffiths@sheffield.ac.uk

KEYWORDS: Fetus, Magnetic resonance imaging, Diagnostic accuracy, Dandy-Walker, Chiari 2 malformation, cisterna magna

ABSTRACT

Objective *To assess the diagnostic and clinical contribution of in utero magnetic resonance (iuMR) imaging in fetuses diagnosed with abnormalities of the posterior fossa as the only intracranial abnormality recognised on antenatal ultrasonography (USS).*

Methods *We report a sub-group analysis of fetuses with abnormalities of the posterior fossa diagnosed on antenatal USS (with or without ventriculomegaly) from the MERIDIAN cohort who had iuMR imaging within 2 weeks of USS and outcome*

reference data were available. The diagnostic accuracy of USS and iuMR are reported as well as indicators of diagnostic confidence and effects on prognosis and clinical management.

Results Abnormalities confined to the posterior fossa according to USS were found in 81 fetuses (67 with parenchymal and 14 with CSF-containing lesions). The overall diagnostic accuracy for detecting an isolated posterior fossa abnormality was 65% for USS and 88% for iuMR (difference=22%, 95% CI: 14.0 to 30.5%, $p<0.0001$). There was an improvement in 'appropriate' diagnostic confidence as assessed by a score-based weighted average' method ($p<0.0001$) and a three-fold reduction in 'high confidence but incorrect diagnoses' was achieved by using iuMR imaging. The prognostic information given to the women after iuMR imaging changed in 44% of cases and the overall effect of iuMR on clinical management was considered to be 'significant', 'major' or 'decisive' in 35% of cases.

Conclusions Our data suggests that any woman whose fetus has a posterior fossa abnormality as the only intracranial finding on USS should have iuMR imaging for further evaluation. This is on the basis of improved diagnostic accuracy and confidence which has substantial effects on the prognostic information given to women and changes in clinical management.

INTRODUCTION

In our previous two published papers related to the MERIDIAN study, we reported sub-groups analyses relating to the investigation of fetuses with apparent isolated ventriculomegaly¹ and isolated abnormalities of the corpus callosum (failed commisuration)² detected on antenatal ultrasonography (USS). In both cases we concluded that *in utero* MR (iuMR) imaging is a powerful adjunct to USS and improves diagnostic accuracy, diagnostic confidence and has a positive clinical impact in a high proportion of cases. The third sub-group studied in this fashion, and reported here, concerns the antenatal USS detection of brain abnormalities apparently confined to the posterior fossa. This includes abnormalities of the cerebellum, brain stem and associated CSF-containing spaces.

This group is different from the previous two, inasmuch as the fetal medicine focus groups that recommend the sub-group analysis recognized that it was likely that the diagnostic performance of USS would be worse than iuMR imaging. This is in contrast to the fetuses with isolated ventriculomegaly and corpus callosum abnormalities in which the focus groups predicted (incorrectly) would be diagnosed accurately by USS in most cases.

This paper reports the diagnostic accuracy and confidence of USS and iuMR for detecting posterior fossa abnormalities and, like the two previous studies, also looks for changes in prognostic information and clinical management of pregnant women brought about by including iuMR imaging in the diagnostic pathway.

METHODS

All of the cases reported in this paper were recruited into the MERIDIAN study and the overarching methodology of the MERIDIAN study is reported elsewhere³ but the parts relevant to this paper are summarised here. Recruitment was from 16 fetal medicine units in the UK and inclusion criteria for the main study were – pregnant women aged ≥ 16 years whose fetus had a brain abnormality detected by USS at a gestational age of 18 weeks or more, with no contraindications to iuMR and who was willing to provide written, fully informed consent to enter the study. This subgroup analysis describes those fetuses with abnormalities confined to the posterior fossa (with or without associated ventriculomegaly), specifically those involving the brainstem or cerebellum (‘parenchymal abnormalities’) and those involving ‘CSF-containing’ lesions. Examples of parenchymal lesions include Dandy-Walker spectrum malformations, Chiari 2 malformations and cerebellar hypoplasia, whilst CSF-containing lesions include enlarged cisterna magna (CM), Blake’s pouch cyst and arachnoid cysts.

Antenatal imaging with ultrasonography and *in utero* MR imaging

The USS studies were performed by appropriately trained NHS consultants in fetal medicine and, after consent was obtained, each brain abnormality was listed using nomenclature from the “*ViewPoint*” antenatal ultrasound reporting software (GE Healthcare, Chalfont St Giles UK) along with an assessment of certainty of diagnosis for each brain abnormality using a 5 point Likert scale⁴. Subsequently, the women had an iuMR examination performed on a 1.5T superconducting clinical MR system at one of six centres. The base requirement for the iuMR study was T2-weighted images of the

fetal brain in the three orthogonal planes and a T1-weighted ultrafast sequence in at least one plane (usually axial). The reporting radiologist was aware of the diagnoses and the level of certainty made on USS from the study paperwork but also had access to the full clinical USS report. The radiologist was required to comment on each brain abnormality recognised on USS (using ‘diagnosis excluded’ if the finding was not present on iuMR) and added extra anatomical diagnoses where appropriate onto a similar form as used for USS. Each entry was accompanied by an indicator of confidence using the same Likert scale as the USS assessment.

Outcome reference data and assessment of diagnostic accuracy

In cases where pregnancy continued and the child survived, outcome reference data (ORD) was obtained from the clinical notes based on a diagnoses made on postnatal neuroimaging studies up to the age of six months. In cases of termination of pregnancy (TOP), stillbirth or neonatal deaths the ORD was based on autopsy and/or post-mortem MR imaging. An independent paediatric neuroradiologist determined whether a full review of ORD by a Multidisciplinary Independent Expert Panel (MIEP) was required. Full review was required unless there was complete and unequivocal agreement between the anatomical findings on USS, iuMR and the ORD. The MIEP consisted of three NHS consultants (neuroradiologist, fetal medicine consultant, and paediatric neurologist) from a centre that did not recruit into MERIDAN and they were asked to judge whether the USS-based diagnoses and iuMR-based diagnoses had complete agreement with the ORD. The primary analysis in MERIDAN centred on participants

who underwent iuMR within 14 days of USS and for whom ORD was available and consisted of a calculation of diagnostic accuracy for USS and iuMR studies defined as;

$[\text{True positives} + \text{True negatives}] / \text{Total number of cases}$

Diagnostic accuracies were calculated for USS and iuMR and compared with ORD using McNemar's.

Assessment of diagnostic confidence

In line with the main paper the first analysis of diagnostic confidence simply described the proportion of USS and iuMR diagnoses made with high and low confidence that were either correct or incorrect. 'High confidence' diagnoses were defined as 70% or 90% certainties and low confidence diagnoses were 10%, 30% or 50% certainties for the purposes of this analysis.

Our previous publication⁵ describes the significant limitations of the conventional assessments of diagnostic confidence, even if the Omary correction⁶ is used. The major limitation occurs because those methods do not require confirmation that the diagnoses are either correct or incorrect (i.e. no ORD are required). All of the cases in this study have ORD and we have chosen to use the 'score-based weighted average' method described by Ng and Palmer⁷ as our preferred method of describing 'appropriate' diagnostic confidence. This approach uses not only diagnostic confidence assessments but also indicators of diagnostic accuracy as provided by the MIEP, specifically: was the overall diagnosis correct for iuMR, was the overall diagnosis correct for USS, which imaging method described the most severe pathology. This aspect was combined with a binary assessment of diagnostic confidence as either 'high' or 'low' as described above. An algorithm modified from Ng and Palmer⁷ (Figure 1) was used to define a route label for each case and hence derive a route score ranging from -4 to +4. Zero indicates no

change in ‘appropriate’ confidence, positive values indicate a benefit from iuMR imaging and negative values indicate that iuMR imaging had a detrimental effect on appropriate diagnostic confidence and the larger the value the greater the effect. The mean, standard deviation and 95% confidence intervals were calculated and one sample t-tests were carried out to determine if the calculated scores differed from zero.

Assessment of effects on prognosis and clinical management

MERIDIAN collected data from the fetal medicine specialists about any changes in clinical management brought about by iuMR as described in detail elsewhere³, but to summarise they were asked if iuMR imaging: a) provided extra diagnostic information, b) led to a change in prognosis and c) led to a change in management (including if TOP was offered as a management option). With respect to analysis of prognostic information, the fetal medicine subspecialists were asked to define what prognostic information was given to the woman on the basis of the USS scan (but before iuMR) based on the following five categories:

- 1) Normal - no worse than the risk to a fetus without a demonstrable brain abnormality
- 2) Favourable - Normal neurological outcome expected in >90% of cases
- 3) Intermediate - Normal neurological outcome expected in 50 to 90% of cases
- 4) Poor - Normal neurological outcome expected in <50% of cases
- 5) Unknown

At the next consultation with the woman (where the iuMR report was available) the clinician recorded the updated prognostic information using the same five categories. For the purposes of description in this report we describe if the prognosis remained the same, worsened or improved after iuMR. This approach is straightforward when

prognoses were in groups 1) to 4) or if the prognosis was ‘Unknown’ on both USS and iuMR. Difficulties arise when the prognosis on one imaging method was given as ‘unknown’ but specified as 1) to 4) on the other. We have elected to interpret:

- USS prognosis ‘unknown’, iuMR prognosis ‘Normal’ or ‘Favourable’ = improved prognosis
- USS prognosis ‘unknown’, iuMR prognosis ‘Intermediate’ = no change in prognosis
- USS prognosis ‘unknown’, iuMR prognosis ‘Poor’ = worse prognosis
- USS prognosis ‘Normal’ or ‘Favourable’, MR prognosis ‘Unknown’ = worse prognosis
- USS prognosis ‘Intermediate’, MR prognosis ‘Unknown’ = no change in prognosis
- USS prognosis ‘Poor’, MR prognosis ‘Unknown’ = no change in prognosis

Clinicians were also asked if TOP was offered because the abnormalities on USS only were sufficient to consider that option under Ground E of the Abortion Act (section 1(1)(d) – substantial risk of serious mental or physical handicap).⁸ They were subsequently asked if the previous decision about offering TOP was still valid after the iuMR information was available.

RESULTS

Intracranial abnormalities confined to the posterior fossa were diagnosed on USS in 81/570 (14.2%) fetuses from the MERIDIAN cohort. 57/81 (70.4%) had their iuMR study between 18-23 weeks in fetuses and 24/81 (29.6%) at ≥ 24 week's gestational age. A parenchymal abnormality confined to the posterior fossa was diagnosed on USS in 67/81 fetuses and a CSF-containing abnormality in 14/81. Associated ventriculomegaly was found on USS in 25/81 (31%) of cases overall and was present in 20% of the fetuses with cerebellar hypoplasia, 29% with Dandy-Walker spectrum abnormalities and 52% of fetuses with Chiari 2 malformations.

Diagnostic accuracy

The diagnostic accuracy data for the sub-group of fetuses with posterior fossa abnormalities is shown in table 1. The label 'any abnormality of the posterior fossa' does not distinguish between the type of posterior fossa abnormality, therefore incorrect diagnoses occur either when the ORD was normal or if a brain abnormality outside the posterior fossa was confirmed on ORD. Using that definition, USS had an overall diagnostic accuracy of 65.4% and the 28 diagnostic errors in that group are described in table 2. ORD reported a normal brain in 18/28 of the USS errors and other supratentorial brain abnormalities in 10/28 of the USS errors (the other brain abnormalities consisted of: 6 agenesis or hypogenesis of the corpus callosum, 2 cortical formation abnormalities, 2 acquired pathology). Analysis of the iuMR imaging of those cases gave a diagnostic accuracy of 87.7%, demonstrating an improvement in diagnostic accuracy of 22.3% (95% CI: 14.0 to 30.5%, $p < 0.0001$) over USS. The 10 errors made on iuMR consisted of eight cases in which the ORD was normal and two cases in which

iuMR imaging failed to detect an abnormality of the corpus callosum shown on ORD. Example cases of agreements and disagreements are shown in figures 2-5.

Parenchymal abnormalities

67/81 (82.7%) of the USS-based diagnoses described a ‘parenchymal abnormality’ of the posterior fossa and the specific diagnoses on USS were:

- Cerebellar hypoplasia in 25/67 (38%) - vermian hypoplasia in 15 fetuses and hypoplasia of the cerebellar hemispheres in 10 fetuses
- Dandy-Walker spectrum abnormalities in 21/67 (31%)
- Chiari 2 malformation in 21/67 (31%)

The label ‘parenchymal abnormality’ in table 1 requires the exact pathological diagnosis of the posterior fossa abnormality to be correct when compared with ORD and ignores the presence or absence of other brain abnormalities. As such, USS made the correct specific anatomical diagnosis in 54/67 fetuses (diagnostic accuracy 80.6%) and iuMR provided the correct diagnosis in 64/67 fetuses (diagnostic accuracy 95.5%). The difference in diagnostic accuracy was 14.9% (95% CI: 5.7 to 24.1%, $p=0.002$) in favour of iuMR.

CSF-containing abnormalities

14/81 of the diagnoses made on USS involved a ‘CSF containing abnormality’, which consisted of eight fetuses with an enlarged CM and six fetuses with abnormal cystic structures (four arachnoid cysts and two unspecified). 3/14 of the cases with an USS diagnosis of a ‘CSF abnormality’ were correct when compared with ORD (diagnostic accuracy 21.4%). The ORD diagnoses in the 11/14 cases of incorrect diagnoses on USS consisted of ‘no brain abnormality’ in eight fetuses, failed commissuration in two cases

and duro-venous thrombosis with ectasia⁹ in one case (Figure 6). The iuMR studies in those 14 fetuses provided the correct diagnosis in 8/14 cases (diagnostic accuracy 57.1%) with a difference in favour of iuMR 35.7% (95% CI -1.6% to 73.0%, p=0.0625). All of the errors on iuMR imaging were cases in which a CSF-containing abnormality was diagnosed but not confirmed on ORD, although a corpus callosum abnormality was also missed in one case.

Diagnostic confidence

Figure 7 presents the proportions of correct and incorrect diagnoses made with high and low diagnostic confidence. High confidence diagnoses were made in 85% of fetuses on USS and 91% of fetuses on iuMR, an increase of 6%. In 17/81 cases (21% of the entire sub-group) a high confidence diagnoses was made on USS that was found to be incorrect on ORD in comparison with 6/81 (7%) on iuMR imaging, indicating a 3-fold reduction. 5/81 (6%) low confidence diagnoses were correct on USS, whilst 4/81 (5%) of low confidence diagnoses were correct on iuMR imaging. As described in the Methods section, diagnostic accuracy data was used in conjunction with diagnostic confidence data in order to calculate a ‘score-based weighted average’ value for each case as shown in figure 8. In 49/81 cases (60%) the score was 0 indicating that iuMR had no effect on diagnostic confidence in those cases, whilst the score was negative in 8/81 cases (10%) indicating a deleterious effect of iuMR on ‘appropriate’ diagnostic confidence (Figure 8). In 24/81 cases (30%) the score was positive indicating an ‘appropriate’ improvement in diagnostic performance. Formal analysis of the score-

based weighted average graph indicates a mean difference of +0.70 (95% CI +0.36 to +1.05, $p < 0.0001$) indicating an improvement in 'appropriate' diagnostic performance.

Prognosis and clinical management

There was incomplete prognostic/clinical management data in 3/81 cases, all from the 'parenchymal abnormality' group. In the 78 cases in which complete prognostic/management data was available, fetal maternal consultants said that iuMR imaging provided extra diagnostic information in 38/78 fetuses (49%) compared with USS. This included 5/14 (36%) from the 'CSF abnormality' group and 33/64 (52%) from the 'parenchymal abnormality' group. The prognostic information category given to women after iuMR imaging changed in 34/78 (44%) cases. In 20 fetuses the prognosis was worse after iuMR including 13 in whom the prognosis had become 'Poor'. In the 14 cases in which the prognosis improved after iuMR, the prognosis was described as 'Normal' in three and 'Favourable' in six fetuses. TOP was offered to 33/78 (42%) women on the basis of the USS findings alone (all from the 'parenchymal abnormality' group) and this increased to 45/78 (58%) after iuMR imaging (44 in the 'parenchymal abnormality' group). In 28 cases TOP was offered both before and after iuMR imaging and in five cases the offer of TOP was reversed on the basis of the iuMR findings. TOP was offered on the basis of the iuMR findings alone in 17 cases. Hence, fundamental changes in the decision to offer TOP occurred in 22/78 cases (28%) and termination of pregnancy was performed in 16/78 (21%) cases. The effect of iuMR on the final choice of clinical management was considered to be: no influence – 8/78, minor influence – 43/78, significant influence – 16/78, major influence – 9/78 and decisive influence – 2/78.

DISCUSSION

In this paper we present the last of three sub-group analyses from the MERIDIAN cohort, all of which were defined by the type of anatomical abnormality described on antenatal USS. The sub-groups were suggested by expert focus groups and consisted of the three commonest fetal neuropathologies encountered during antenatal USS; ventriculomegaly, failed commissuration and posterior fossa abnormalities. The subject of this report, posterior fossa abnormalities, is different from the other two in several ways - the first, and major, difference relates to how the sub-groups are formed. Ventriculomegaly is a single specific diagnosis relating to the size of the lateral ventricles (although it can result from a multitude of causes) and failed commissuration refers to varying degrees of underdevelopment of a single structure, the corpus callosum. In contrast, posterior fossa abnormalities form a heterogenous group with a range of different pathologies some of which are likely to be conspicuous on imaging, and hence easy to detect, whilst others will be more subtle. For example, Chiari 2 malformation was detected accurately on USS and iuMR in all cases. In spite of specific examples such as that, the expert focus groups believed that the diagnosis of posterior fossa abnormalities is difficult on USS and iuMR imaging was likely to have a larger positive effect on diagnostic accuracy and confidence when compared with fetuses with ventriculomegaly or failed commissuration.

The overall improvement in diagnostic accuracy of iuMR imaging over USS shown in this study was based on an approximately 23% increase (95% CI: 65 to 88%), double the rate of extra brain abnormalities being found in fetuses in the isolated

ventriculomegaly sub-group (10%)¹. In contrast, the improvement in diagnostic accuracy for detecting posterior fossa abnormalities was substantially lower than the improvement in cases of failed commissuration, in which iuMR improved diagnostic accuracy from 34% to 95%. There was also a much clearer improvement in diagnostic confidence using iuMR imaging in the failed commissuration group compared with posterior fossa abnormalities, although the latter still showed a statistically significant improvement over USS. The comparative diagnostic performance of USS and iuMR imaging was closest for parenchymal abnormalities where USS had a diagnostic accuracy of 81% (when the nature of the posterior fossa pathology alone was considered) compared with 96% for iuMR, although the difference still indicates an improvement for iuMR imaging. One important confounding factor to consider when interpreting this data concerns the cases of Chiari 2 malformations. Those are posterior fossa parenchymal abnormalities and, hence, were eligible for recruitment into MERIDIAN but there is an invariable association between Chiari 2 malformation and open spinal dysraphism. The spinal pathology is often gross and easily detected on USS and could potentially bias the results by ‘signposting’ the presence of the Chiari 2 malformation that would otherwise have been overlooked on antenatal USS. There were 21 cases of Chiari 2 malformation in our sub-group and in all of those fetuses the USS, iuMR and ORD were all in agreement. If the fetuses with Chiari 2 malformations are excluded from analysis, the diagnostic accuracy for USS in detecting parenchymal abnormalities becomes 72% (33/46 correct) and for iuMR 93% (43/46 correct).

Although the numbers in our sub-group with CSF-containing abnormalities were small (n=14), the diagnostic performance for both USS and iuMR in attempting to define

CSF-containing abnormalities is worryingly poor (diagnostic accuracy for USS 21%, diagnostic accuracy for iuMR 57%). This is the only diagnostic accuracy analysis of the MERIDIAN data performed to date that has failed to show a statistically significant improvement of iuMR over USS ($p=0.0625$), although this subgroup comprised just 14 fetuses. The commonest error category in this group was a normal ORD report but both imaging modalities reporting an enlarged CM. It is interesting to speculate why the performance of both USS and iuMR imaging are poor for this particular type of pathology as there are no recognised specific technical or anatomical reasons to explain the sub-optimal performance. One possibility is the antenatal USS and iuMR examinations were correct at the time of the imaging studies in that enlarged CM is a temporary, but normal, feature in some fetuses which regresses and is no longer present in the neonate or infant¹⁰. Differential growth of the cerebellum/bony posterior fossa and postnatal changes in CSF resorption are possible mechanisms to explain this supposition. Another possibility is that the ORD is wrong and the reported enlarged CM are indeed abnormal and could be explained by the mechanism by which ORD was collected in this study. It was not possible to insist on postnatal MR examinations in this study, rather we had to rely on the neuroimaging that had been obtained for clinical purposes up to the age of 6 months. It is highly likely that most babies with enlarged CM as the only intracranial finding will have no evidence of neurodevelopmental problems and therefore postnatal MR examinations are unlikely to be requested. As a result the only postnatal imaging will be trans-fontanelle cranial ultrasonography which is known to be poor at showing the posterior fossa^{11,12}, particularly the extra-axial spaces. As such, an enlarged CM could be missed. Both of the suggestions to explain the poor performance of USS and iuMR imaging are easily testable and future imaging

studies could be designed to answer this question and the results will be important in terms of counselling given to a woman whose fetus has an enlarged CM.

Even in its present form, however, the results of iuMR imaging had a substantial impact on prognostication and clinical management in cases of fetal posterior fossa abnormalities. The prognostic category changed in 44% of cases after iuMR imaging and in slightly more than half of those cases the prognosis was worse after iuMR. The overall effect of iuMR imaging was to increase the rate at which TOP was offered to women, approximately 42% on the basis of the USS findings alone to approximately 58% after the iuMR imaging. Five women were offered TOP on the basis of USS but the offer reversed after iuMR imaging so the individual rate of changing the offer of TOP was 17/78 (approximately 22%). The effects on clinical management were considered to be significant, major or decisive in 35% of pregnancies.

The perceived problems about coming to the correct anatomical diagnosis of posterior fossa abnormalities using USS predicted by the expert focus groups were realised, as was the improvement brought about by supplementing the USS examination with iuMR scans. The improvements in diagnostic accuracy and confidence arising from performing iuMR studies was accompanied by changes of prognosis and clinical management in approximately 40% of cases. We conclude, therefore, that iuMR imaging should be offered routinely to women whose fetus has a posterior fossa abnormality detected on antenatal USS.

ACKNOWLEDGMENTS

This project was funded by the National Institute for Health Research Health Technology Assessment Programme (project number 09/06/01). The views and opinions expressed therein are those of the authors and do not necessarily reflect those of the Health Technology Assessment Programme, NIHR, NHS or the Department of Health.

REFERENCES

1. Griffiths PD, Brackley K, Bradburn M, Connolly DJA, Gawne-Cain M, Griffiths DI, Kilby MD, Mandefield L, Mooney C, Robson SC, Vollmer B, Mason G. Anatomical subgroup analysis of the MERIDIAN cohort: Ventriculomegaly (under review)
2. Griffiths PD, Brackley K, Bradburn M, Connolly DJA, Gawne-Cain M, Griffiths DI, Kilby MD, Mandefield L, Mooney C, Robson SC, Vollmer B, Mason G. Anatomical subgroup analysis of the MERIDIAN cohort: Failed commissuration (under review)
3. Griffiths PD, Bradburn M, Campbell MJ, Cooper CL, Graham R, Jarvis D, Kilby MD, Mason G, Mooney C, Robson SC, Wailoo A. Use of MRI in the diagnosis of fetal brain abnormalities in utero (MERIDIAN): a multicentre, prospective cohort study. *The Lancet* 2016; doi: 10.1016/S0140-6736(16)31723-8
4. Likert R. A technique for the measurement of attitudes. *Archives of Psychology* 1932; **22** : 1–55
5. Griffiths PD, Bradburn M, Campbell MJ, Cooper CL, Jarvis D, Kilby MD, Mason G, Mooney C, Robson SC, Wailoo A. Change in diagnostic confidence brought about by using *in utero* MR imaging for fetal structural brain pathology: Analysis of the MERIDIAN cohort. *Clin Radiol* (accepted, pending publication)
6. Omary RA, Kaplan PA, Dussault RG, Hornsby PP, Carter CT, Kahler DM, Hillman BJ. The impact of ankle radiographs on the diagnosis and management of acute ankle injuries. *Academic Radiology* 1996; **3**(9) : 758–765

7. Ng CS, Palmer CR. Analysis of diagnostic confidence and diagnostic accuracy: a unified framework. *The British Journal of Radiology* 2007; **80**(951) : 152–160.
8. Abortion Act 1967 section 1
9. Fanou EM, Howe DT, Joy H, Morris S, Russell S, Griffiths PD. The use of in utero MR in prenatal investigation of enlarged dural venous sinuses with thrombus. *Pediatric Radiology* 2013; **43**(12) : 1591-1598
10. Gandolfi Colleoni G, Contro E, Carletti A, Ghi T, Campobasso G, Rembouskos G, Volpe G, Pilu G and Volpe P. *Prenatal diagnosis and outcome of fetal posterior fossa fluid collections* 2012; **39** : 625-631
11. Luna, JA and Goldstein RB. Sonographic visualization of neonatal posterior fossa abnormalities through the posterolateral fontanelle. *AJR Am J Roentgenol* 2000; **174**(2) : 561-567
12. Steggerda SJ, de Bruïne FT, Smits-Wintjens VE, Walther FJ, van Wezel-Meijler G. Ultrasound detection of posterior fossa abnormalities in full-term neonates. *Early Human Development* 2012; **88**(4) : 233-239

CONFLICT OF INTEREST

The authors confirm that there are no conflicts of interest.

LEGENDS

Figure 1. The algorithm used to provide the score-based weighted average data used to assess changes in appropriate confidence (modified from Ng and Palmer⁷).

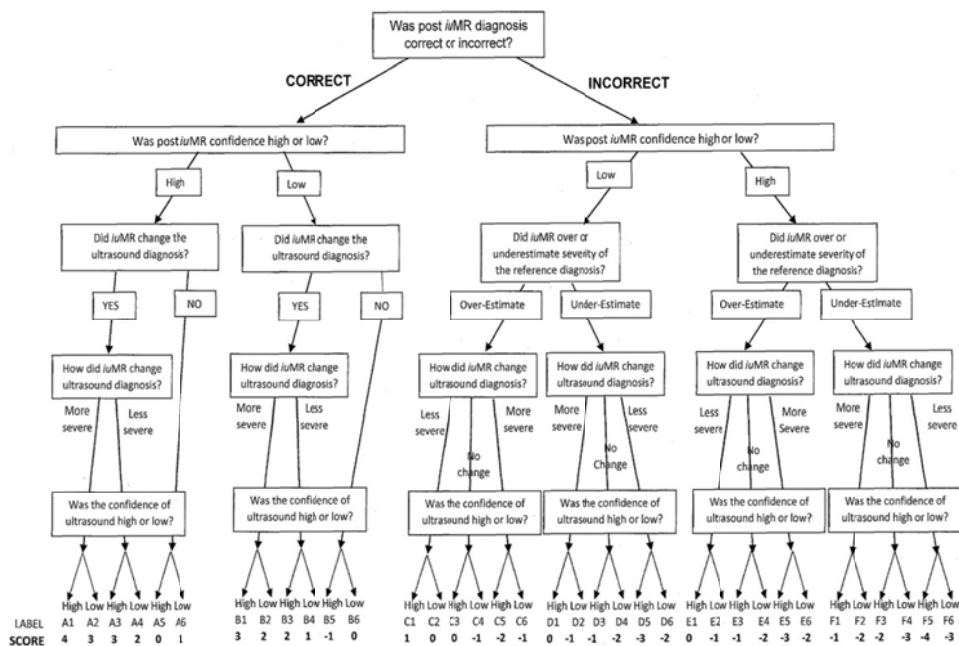


Figure 2. A case of complete agreement between ultrasound, in utero MR imaging and outcome reference data. The fetus was recruited into the MERIDIAN study from ultrasonography on the basis of a Chiari 2 malformation and ventriculomegaly and in utero MR imaging was performed at 24 weeks gestational age. Severe ventriculomegaly is confirmed on the axial iuMR image (2a) and the effacement of the external CSF spaces and disruption of the cavum septum pellucidum on the coronal image (2b) indicates hydrocephalus. Sagittal image (2c) shows a severe Chiari 2 malformation with a small posterior fossa and cerebellar tissue herniating into the cervical spinal canal. A large spinal abnormality (myelomeningocele) is also shown.

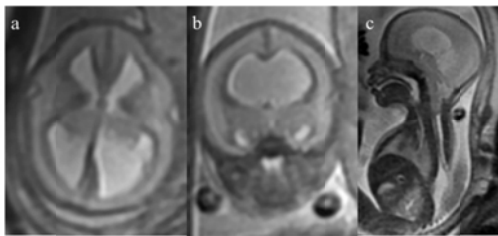


Figure 3. A case of complete agreement between ultrasound, in utero MR imaging and outcome reference data. The fetus was recruited into the MERIDIAN study from ultrasonography on the basis of a Dandy-Walker malformation and ventriculomegaly and in utero MR imaging was performed at 21 weeks gestational age. There is severe hypoplasia of the cerebellar vermis and increased volume of the posterior fossa present on the sagittal and axial iuMR images (3a and 3b) in keeping with a Dandy-Walker malformation. Mild ventriculomegaly is demonstrated on the axial image at the level of the trigones of the lateral ventricles (3c).

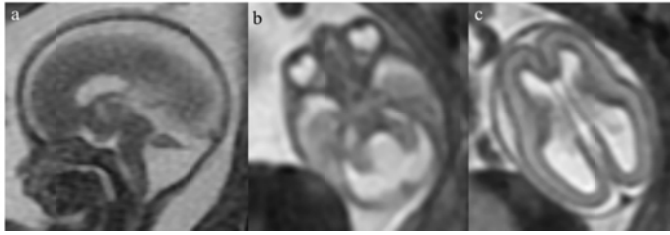


Figure 4. A case of disagreement between ultrasound and outcome reference data with the correct diagnosis being made on in utero MR imaging. The fetus was recruited into the MERIDIAN study from ultrasonography on the basis of a Dandy-Walker malformation and ventriculomegaly and in utero MR imaging was performed at 21 weeks gestational age. There is severe hypoplasia of the cerebellar vermis and mild increased volume of the posterior fossa present on the sagittal and axial iuMR images (4a and 4b) in keeping with a Dandy-Walker malformation. Mild ventriculomegaly was confirmed on the axial image (4c) but there is also hypoplasia of the corpus callosum (arrowed on 4a and 4c and confirmed on autopsy).

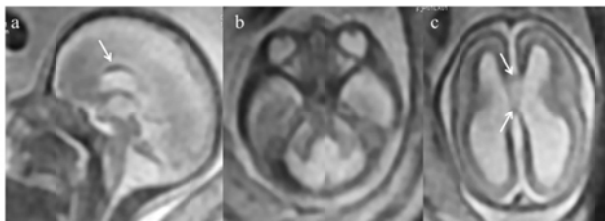


Figure 5. A case of disagreement between ultrasound and outcome reference data with the correct diagnosis being made on in utero MR imaging. This fetus was the result of a dizygotic twin pregnancy and was recruited into the MERIDIAN study from ultrasonography on the basis of a cerebellar hypoplasia. The other twin was normal. In utero MR imaging was performed at 25 weeks gestational age and confirmed a small cerebellum (in terms of transcerebellar diameter – figure 5a) but also showed lack of the indentation at the site of the normal cerebellar vermis (arrowed 5a). The inferior

superior vermian height appears to be normal (5b) but there is none of the normal morphology of the cerebellar vermis. This indicates non-formation of the vermis and abnormal continuity of the cerebellar hemispheres over the mid-line i.e. rhombencephalosynapsis. These features were confirmed on postnatal imaging (5c and 5d).

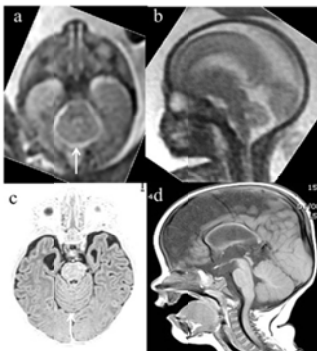


Figure 6. A case of disagreement between ultrasound and outcome reference data with the correct diagnosis being made on in utero MR imaging. The fetus was recruited into the MERIDIAN study from ultrasonography on the basis of an abnormal cystic abnormality in the posterior fossa and in utero MR imaging was performed at 29 weeks gestational age. There is a large extra-axial mass lesion centred on the venous confluence (6a and 6b) that has heterogenous signal on in utero MR images - low signal centre and high signal rim on both T2 (6b) and T1-weighted (6c) images. This is likely to represent clotted blood at different stages of evolution. It extends into the superior sagittal sinus, deep venous system (6a) and transverse sinuses (6d), all of which are enlarged. A diagnosis of duro-venous sinus ectasia with thrombosis was made. The diagnosis was confirmed on postnatal MR imaging at 1 day of age (6e-6g) which showed partial resolution. No brain parenchymal abnormality was present. The frontal

projection of the MR venography study shows that the transverse and sigmoid sinuses are occluded.

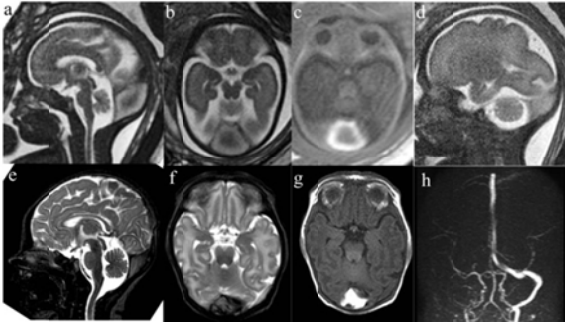


Figure 7. Bar charts of ‘high confidence’ (70 or 90%) and ‘low confidence’ (10, 30 or 50%) diagnoses made on ultrasonography and in utero MR imaging. The red parts of the bar chart indicate those diagnoses that were incorrect in comparison with outcome reference data. See text for details.

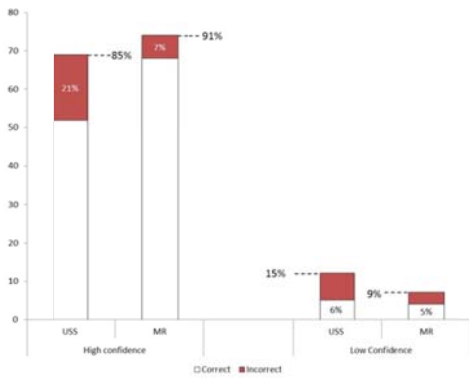


Figure 8. Changes in diagnostic confidence using the route score method for Posterior fossa cases (n=81). There is a significant increase (0.7, $p<0.0001$) in favour of positive scores (see text for details and interpretation).

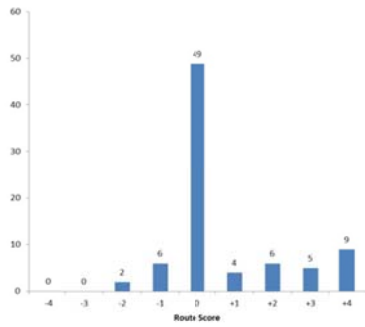


Table 1 Cases of isolated abnormalities of the posterior fossa diagnosed on USS and the equivalent cases on iuMR compared with ORD.

Subgroup	USS Diagnoses			iuMR Diagnoses		Comparison of diagnostic accuracy	
	n	Number incorrect	Diagnostic accuracy	Number incorrect	Diagnostic accuracy	Difference (95% CI**)	p-value*
<i>Any abnormality of the posterior fossa</i>	81	28	65.4%	10	87.7%	22.3 (14.0, 30.5%)	<0.0001
Parenchymal abnormality	67	13	80.6%	3	95.5%	14.9 (5.7, 24.1%)	0.0020
CSF abnormality	14	11	21.4%	6	57.1%	35.7 (-1.6, 73.0%)	0.0625

The subgroup ‘any abnormality of the posterior fossa’ allows any diagnosis of isolated posterior fossa abnormality to be correct when compared with ORD, whereas subgroups ‘parenchymal’ and ‘CSF’ require the more restrictive diagnoses described in the text to be correct. * McNemar’s test between USS and iuMR correct diagnoses.

Table 2 Summary data on the 28 cases in which posterior fossa abnormalities diagnosed on USS were incorrect when compared with outcome reference data from the first line of results in table 1.

Case	USS diagnosis	Posterior fossa abnormality on ORD	Other brain abnormality on ORD	iuMR weeks	Posterior fossa abnormality on iuMR	Other brain abnormality on iuMR
43	DWS	DWS	Hypoplasia CC	20	DWS	*No
55	Hypoplastic vermis	Normal	No	29	*Hypoplastic vermis	No
148	Hypoplastic vermis	Normal	No	21	*Hypoplastic vermis	No
170	DWS	DWS	Hypoplasia CC	21	DWS	Hypoplasia CC
230	Hypoplastic vermis	Normal	No	21	Normal	No
432	DWS	Intracerebellar haemorrhage	Periventricular leukomalacia	35	Intracerebellar haemorrhage	Periventricular leukomalacia
466	Hypoplastic hemisphere.	Hypoplastic hemisphere.	Lissencephaly	29	Hypoplastic hemisphere.	Lissencephaly
506	Hypoplastic vermis	Normal	No	33	Normal	No
569	DWS	DWS	Focal megalencephaly (and agenesis CC)	22	DWS	Agenesis CC Focal megalencephaly
578	DWS	DWS	Hypoplasia CC	21	DWS	Hypoplasia CC
700	Hypoplastic	Normal	No	28	*Hypoplastic	No

	hemisphere.				hemisphere.	
726	Hypoplastic hemisphere.	Rhombencephalosynapsis	Hypoplasia CC	26	Rhombencephalosynapsis	Hypoplasia CC
739	Hypoplastic hemisphere.	Normal	No	23	Normal	No
765	Hypoplastic vermis	Normal	No	19	Normal	No
769	Hypoplastic vermis	DWS	Hypoplasia CC	20	DWS	Hypoplasia CC
777	DWS	Normal	No	33	Normal	No
855	Hypoplastic vermis	Normal	No	21	Normal	No
865	Hypoplastic vermis	Normal	No	35	Normal	No
1056	Hypoplastic vermis	Normal	No	22	Normal	No
97	Arachnoid cyst	Normal - Mass effect only	Duro-venous sinus ectasia with thrombosis	29	Mass effect only	Duro-venous sinus ectasia with thrombosis
281	Enlarged CM	Normal	No	21	*Enlarged CM	No
393	Posterior fossa cyst	Normal	No	20	*Posterior fossa cyst	No
476	Posterior fossa cyst	Normal	No	20	*Posterior fossa cyst	No
551	Enlarged CM	Normal	No	22	*Enlarged CM	No

555	Enlarged CM	Normal	No	29	Normal	No
607	Enlarged CM	Normal	No	32	Normal	No
889	Enlarged CM	Hypoplastic vermis	Agenesis of the CC	26	*DWS	*No
1087	Enlarged CM	Normal	No	22	*Enlarged CM	No

* indicates that *in utero* MR imaging diagnosis was also incorrect. Abbreviations used: ORD = outcome reference data, DWS = Dandy-Walker spectrum, CC = corpus callosum, CM = cisterna magna