

Infections due to Dysregulated Immunity: An emerging complication of Cancer Immunotherapy

Tommaso Morelli^{1,2}, Kohei Fujita³, Gil Redelman-Sidi⁴, Paul Elkington^{1,2}

¹ NIHR Biomedical Research Centre, School of Clinical and Experimental Sciences, Faculty of Medicine, University of Southampton, Southampton, United Kingdom.

² Institute for Life Sciences, University of Southampton, Southampton, United Kingdom.

³ Division of Respiratory Medicine, Centre for Respiratory Diseases, National Hospital Organization Kyoto Medical Centre, Kyoto, Japan

⁴ Division of Infectious Diseases, Memorial Sloan Kettering Cancer Centre, New York, USA

Address for correspondence:

Professor Paul Elkington

Clinical and Experimental Sciences

University of Southampton, Southampton SO16 1YD

Tel.: 00 44 23 8079 5928

E-mail: p.elkington@soton.ac.uk

Abstract

Immune checkpoint inhibitors (ICIs) have revolutionised cancer treatment. However, immune related adverse events (irAEs) are a common side-effect, which can mimic infection. Additionally, treatment of irAEs with corticosteroids and other immunosuppressant agents can lead to opportunistic infection, which we have classed as ImmunoTherapy Infections due to ImmunoSuppression (ITI-IS). However, emerging reports demonstrate that some infections can be precipitated by ICIs in the absence of immunosuppressive treatment, in contrast to the majority of reported cases. These infections are characterised by a dysregulated inflammatory immune response, and so we propose they are described as ImmunoTherapy Infections due to Dysregulated Immunity (ITI-DI). This review summarises the rapidly emerging evidence of these phenomena and proposes a new framework for considering infection in the context of cancer immunotherapy.

Introduction

In 1957 Macfarlane Burnet wrote “The failure in cancer is due not to any weakness of the organism, but to a change in the character of the cells, rendering them in one way or another insusceptible to the normal control”.¹ Subsequently, evading immune destruction was identified as a critical hallmark of cancer.² The 2018 Nobel prize was awarded to James Allison and Tasuku Honjo for the discovery that cancer cells could exploit programmed cell death protein 1 (PD-1) and cytotoxic T lymphocyte associated protein 4 (CTLA-4) signalling to avoid immune destruction.³

PD-1 is an immune checkpoint molecule expressed on effector T cells and binds to PD-L1 and PD-L2 on antigen presenting cells (APCs). Tumour cells can also express PD-L1 as a method of evading immune destruction, whereby PD-1/L1 signalling suppresses effector T cell priming and proliferation. CTLA-4 is another co-inhibitory receptor expressed on effector T cells. CTLA-4 competes with the costimulatory receptor CD28 on effector T cells for binding with activation ligands CD80/86, found on APCs. CD28 binding to CD80/86 is essential for T cell receptor (TCR) signalling and hence CTLA-4, which binds to CD80/86 with greater affinity, effectively prevents effector T cell activation. CTLA-4 and PD-1 are expressed on effector T cells following chronic, sustained antigen exposure.⁴⁻⁶

PD-1 and CTLA-4 signalling thus acts as a “brake” to balance and prevent an over-exuberant damaging immune response, for example in chronic infection. PD-1/PD-L1 signalling can be inhibited using monoclonal antibodies against PD-1 (e.g. pembrolizumab, nivolumab) and PD-L1 (e.g. durvalumab, atezolizumab, avelumab). CTLA-4 signalling can similarly be blocked using monoclonal antibodies such as ipilimumab and tremelimumab. Immune checkpoint inhibitors (ICIs) have revolutionised cancer treatment, with improved survival demonstrated in many forms of cancer, including lung cancer, melanoma, colorectal cancer, hepatocellular carcinoma, renal cell carcinoma, bladder cancer, Merkel cell carcinoma and Hodgkin’s lymphoma.⁴ ICIs require close monitoring as they are associated with autoimmune phenomena known as immune related adverse events (irAEs).⁴

56

57 **Immune Related Adverse Events (irAEs)**

58 IrAEs are a common side effect of ICIs, with an incidence between 54%-76% according to a
59 metanalysis of trial data.⁷ IrAEs can affect any body system and management often involves
60 treatment with glucocorticoids such as prednisolone and other immunosuppression such as anti-TNF
61 therapy for steroid refractory cases. From the pulmonary perspective, immune related pneumonitis
62 occurs more commonly with PD-1 blockade and has several radiological presentations including
63 cryptogenic organising pneumonia, nonspecific interstitial pneumonia, hypersensitivity pneumonitis,
64 acute interstitial pneumonia and pulmonary sarcoid reactions.⁵ Combination ICI therapy appears to
65 increase the risk of irAEs.⁸ The pathogenesis of irAEs may be mediated by T cell autoimmunity,
66 impaired regulatory T Cell (Treg) function, TH17 helper T cells and T cell mediated autoantibodies.⁴
67 Notably, irAEs can mimic infection.⁹ Recently it has been hypothesised that immune checkpoint
68 blockade may cause increased immune recognition of commensal bacteria, such as gut microbiota,
69 perhaps via attenuated Treg function, and this immune recognition of commensal bacteria can cause
70 expansion of TH17 cells that have the potential to migrate and potentially cause irAEs.¹⁰

71 **Consequences of Natural Immune Checkpoint Loss of Function**

72 Immune checkpoints help prevent activity against self. Consequently, polymorphisms in CTLA-4 and
73 PD-1 are associated with autoimmune sequelae such as Addison's disease, coeliac disease, Graves'
74 disease, type 1 diabetes mellitus, myasthenia gravis, rheumatoid arthritis, and systemic lupus
75 erythematosus.^{4 6}

76 In addition, genetic mutations in these receptors predict that pharmacological targeting of immune
77 checkpoints may have infectious complications. CHAI (CTLA-4 haploinsufficiency with autoimmune
78 sequelae) and LATAIE (LRBA deficiency with autoantibodies, regulatory T cell defects, autoimmune
79 infiltration and enteropathy) are human genetic disorders associated with deficient CTLA-4

expression and function. CHAI and LATAIE manifest with multiorgan lymphocytic infiltration, T_{reg} defects and autoantibody production and are also associated with recurrent infections, particularly respiratory infections.¹¹ A review of the phenotype of LATAIE patients revealed 71% suffered from recurrent infections (upper respiratory tract, lower respiratory tract and urinary). Reported bacterial infections included a range of pathogens, such as *Escherichia coli*, *Klebsiella pneumoniae*, *Haemophilus influenzae*, *Pseudomonas aeruginosa*, *Campylobacter*, and *Staphylococcus aureus*. Reported viral infections include *cytomegalovirus*, *adenovirus*, *norovirus*, and *varicella zoster*, and candida infections are also described.¹² Although these genetically determined phenotypes have more severe manifestations than CTLA-4 associated irAEs, they provide some insight into the natural consequences of loss of CTLA-4 function. Interestingly CTLA-4 mutations have also been associated with more severe tuberculosis infection in an African population study.¹³ With Respect to PD-1/PD-L1, although there are no human congenital diseases associated with deficiency, PD-1 deficient mice are highly susceptible to tuberculosis infection.^{14 15}

Given the emerging evidence of increased infection in patients treated with ICIs, and evidence that immune checkpoint deficiency can be associated with recurrent infections, we were interested in evaluating the infectious sequelae of ICI therapy. Furthermore, we aimed to characterise the pattern of these infectious complications to inform future clinical management strategies and the associated research agenda.

Literature Search

We performed a literature search to identify reports of adult cancer patients who were found to have developed infections after ICI initiation. The search protocol was registered on PROSPERO (CRD 4202141634, see Appendices 1-3). We searched Medline (Ovid 1996- February week 4 2021) using advanced search, for the following keywords: ("Infection" or "Infectious Disease") and ("Immune checkpoint inhibitor" or "PD-1" or "PD-L1" or "CTLA-4"). Additional limits were placed to include articles relevant to humans and those published in the English language. This search yielded 1294

results. Thirty-four additional relevant studies were identified through co-author suggestion, references and citations. After screening for suitability by viewing the title, abstract, introduction and conclusion, and removing duplicates, 95 full text articles were assessed. Seventy-nine studies were included for analysis (Figure 1). Information on cancer type, ICI used, concurrent immunosuppression and available descriptive statistics were collected. Table S1 summarises the studies of immunotherapy associated infection.

Prospective Randomised Clinical Trial Data

Trial data has not demonstrated a significantly increased rate or risk of infection following ICI treatment.¹⁶ A review of Phase I trial data revealed infection-related adverse events in 18% of patients and the odds ratio of infection was not statistically different from molecular targeted agents for cancer.¹⁷ One study of patients with non-small cell lung cancer (NSCLC) treated with pembrolizumab reported complications of pneumonia (1.5%), lung infection (0.3%), oral candidiasis (0.3%) and urinary tract infection (0.3%).¹⁸ Another RCT reported a case of pneumonia and severe *Varicella zoster* infection following nivolumab for NSCLC.¹⁹ Eight cases of drug related infection, including one severe *Varicella zoster* infection, were reported in a nivolumab trial for melanoma.²⁰ Sepsis following atezolizumab for bladder cancer has also been reported.²¹ However, while RCTs are the gold standard for determining treatment efficacy by minimising bias, they do not adequately assess all potential treatment harms, especially if infrequent.²² Typically these only come to light in post-marketing surveillance when greater numbers of patients are treated.²³ Additionally whilst the total reported infections is small, there may be underreporting in trials as causality to ICIs is not clearly established. Thus, analysis of other forms of data such as clinical observational data is required.

Opportunistic Infections associated with irAE treatment

The European Society of Clinical Microbiology and Infectious Diseases (ESCMID) provided a consensus statement which suggested that ICIs do not intrinsically increase the risk of infection, but rather immunosuppressive therapy to treat irAEs can predispose to opportunistic infection.¹⁶ This followed a retrospective cohort review from Del Castillo et al who analysed records 740 melanoma patients who received ICIs over a four year period and recorded the number of infections requiring hospitalisation or anti-microbial treatment.²⁴ Seven percent of patients developed infection and 17% of these patients died. The vast majority (73.2%) of patients received CTLA-4 blockade with ipilimumab, 14.9% had PD-1 blockade, while 11.7% had combination ICI therapy. Eighty-five percent of infections were bacterial with 13/23 being pneumonia. Two cases of invasive pulmonary aspergillosis, three *Pneumocystis jirovecii* pneumonia, one candidemia and one strongyloidiasis case were reported. Risk factors for infection included corticosteroid administration (OR 7.71 p <0.0001), infliximab (OR 4.74 p<0.0001) and combined PD-1/CTLA-4 blockade (OR 3.26 p 0.0017).²⁴

There are multiple case reports which have also highlighted multiple instances of opportunistic infection following irAE immunosuppression with a variety of causative pathogens including *Aspergillus fumigatus*,²⁵⁻²⁸ *Pneumocystis jirovecii*,²⁹⁻³¹ *JC virus*,³², *Cytomegalovirus*³³ and *Campylobacter*³⁴ (Summarised in Table 1). These reports highlight the need to have a low threshold of investigation for opportunistic infection following irAE treatment and consideration of *Pneumocystis jirovecii* prophylaxis. In addition to prior immunosuppressive cancer treatments, comorbidities such as COPD in lung cancer patients and the immunosuppressive tumour microenvironment are risk factors for infections^{35 36}.

ICI-associated infection independent of immunosuppression

Whilst the predominant infection risk post ICI treatment is likely to be due to immunosuppression, there is mounting evidence of a second mechanism that leads to increased incidence of infection. For example, Fujita et al reviewed 167 records of patients who received nivolumab for non-small cell

lung cancer and 19.2% (32 patients) were treated for infection.³⁷ There were 33 infections, 78.1% were bacterial and included *Streptococcus pneumoniae*, *Haemophilus influenzae*, *Klebsiella pneumoniae*, methicillin resistant *Staphylococcus aureus* (MRSA), methicillin sensitive *Staphylococcus aureus* (MSSA), *Staphylococcus schleiferi*, *Mycobacterium tuberculosis* and other unknown presumed bacterial infection. 6.3% were fungal and included *Aspergillus fumigatus* and *Candida albicans* infection, while 18.8% were viral and included *Varicella* and *Influenza*. Diabetes significantly increased the risk of infection (OR 3.61 p =0.028).³⁷ Of note, this study exclusively analysed PD-1 blockade in the form of nivolumab. Unlike the Del Castillo study, there was no significant difference in the number of infections with use of corticosteroids or other immunosuppressive agents, suggesting an alternative mechanism.

Kanjanapan and Yip recently published a cohort study of 327 patients with primarily NSCLC (36%) and melanoma (47%).³⁸ The majority (77%) of patients received PD-1/PD-L1 therapy, 9% received CTLA-4 therapy, and 14% received combination therapy. The rate of infection up to 12 months post immunotherapy was 27%, age was the only identified risk factor for infections post ICI initiation (HR 1.73 p= 0.04), while corticosteroid use and diabetes mellitus were not risk factors for post ICI infection. The rate of infection in the pre-ICI period was 34%, but notably infectious episodes were defined through positive culture or polymerase chain reaction potentially allowing inclusion of commensal colonisation such as *Staphylococcus aureus* on the skin (55 identified in the pre-ICI period and defined as infection). Furthermore, given the long study period of 7 years it is not possible to directly compare the rates of infection pre and post ICI. However, there was still a significant number of infections in the post ICI period and corticosteroids were not a statistically significant risk factor.³⁸

Furthermore, a recent study retrospectively evaluated infectious sequelae in 200 patients in a French registry, treated with PD-1 (98.5%), and PD-L1 inhibitors (1.5%). 60% of patients had melanoma, 35.5% had NSCLC.³⁹ Infection occurred in 18% between 19 and 132 days after ICI

initiation, of which 58.3% were suspected pulmonary infection which improved with antibiotics, 19.4% were skin infections, 19.4% urinary tract infections and 2.9% GI infection. There were no cases of *Pneumocystis jirovecii* or other typical opportunistic infections. No association with corticosteroids, or other immunosuppressant medication, was reported in this study, again suggesting that immunosuppression was not the primary driver.³⁹

These more recent studies together suggest that other factors other than corticosteroids and immunosuppression may play a role in post ICI infection. There are diverse reports of infection, in which it appears the hyper-inflammatory dysregulated immunity associated with ICIs drives pathogenesis. We propose these can be characterised as ImmunoTherapy Infections due to Dysregulated Immunity (ITI-DI), to distinguish them from ImmunoTherapy Infections due to ImmunoSuppression (ITI-IS). ITI-DI may be considered an entirely different pathological mechanism, whereby the excessive host immune response due to inhibition of immune checkpoints counter-intuitively favours the pathogen (Figure 2).

Emerging examples of ImmunoTherapy Infections due to Dysregulated Immunity (ITI-DI)

***Mycobacterium tuberculosis* and atypical mycobacterial infection**

Tuberculosis reactivation was one of the first ICI-associated infections to be described. Currently there are at least nineteen case reports of *Mycobacterium tuberculosis* (Mtb) reactivation following PD-1/PD-L1 blockade⁴⁰⁻⁵⁵ (Figure 3 and Table S1). A review of the US Food and Drug Administration Adverse Events Reporting (FAERS) system for the incidence of Mtb revealed 72 cases of Mtb following PD-1/PD-L1 blockade. The reporting odds ratio for Mtb infection with PD-1/PD-L1 inhibitors was 1.79 (95% CI, 1.42 to 2.26) ($p < 0.0001$),⁵⁶ demonstrating increased risk of active TB. In addition, due to the clinical similarity in features of cancer progression and mycobacterial infection, it seems likely that cases are underreported through underdiagnosis.⁵⁵ Similarly, analysis of a single centre cohort of 297 patients in Japan with lung cancer receiving treatment with pembrolizumab, nivolumab, atezolizumab or durvalumab revealed an incidence of Mtb reactivation of 1.7%

developing 22-398 days after initiation of ICI treatment.⁵⁷ This is higher than the incidence of Mtb reactivation in lung cancer reported in the 1980s, when generally higher doses of cytotoxic chemotherapy were used.⁵⁸ Also, a single centre cohort in South Korea identified 3 cases of Mtb, and calculated an incidence rate of 394.4 per 100, 000 person years, higher than the rate in the South Korean population in 2018 and previous studies that included patients with lung cancer.⁵⁹ Finally, a single centre cohort in Singapore showed that 4/191 (2.09%) of patients developed Mtb reactivation following PD-1/PD-L1 blockade.⁶⁰

Atypical mycobacterial infection (AMI) has also been associated with immunotherapy. We found four cases of atypical mycobacterium infection following PD-1/PD-L1 immunotherapy in the absence of immunosuppression.^{61 62} Analysis of the FAERS database revealed thirteen cases of AMI following PD-1/L1 blockade, similarly suggesting elevated risk of infection. The reporting odds ratio for AMI was 5.49 (CI, 3.15 to 9.55 $p < 0.0001$).⁵⁶

In terms of the underlying mechanism, transgenic murine studies have demonstrated that PD-1 knockout mice had increased susceptibility to Mtb infection, succumbing even more rapidly than IFN- γ deficient mice^{14 15}. In a human 3D cell culture system, PD-1 blockade leads to excessive cytokine secretion, and TNF- α may play a central role⁶³. Similarly, TB infected macaques given anti-PD-1 antibodies develop worse disease, have higher bacterial loads as well as elevation of multiple inflammatory cytokines, compared to non-PD-1 treated macaques.⁶⁴ Notably these studies suggest PD-1 blockade negatively affects host-Mtb interaction even in the absence of any immunosuppression, favouring pathogen proliferation over host control due to a dysregulated immune response.

These emerging clinical observations, animal modelling and advanced cell culture modelling studies all suggest that disruption of the PD-1/PD-L1 axis results in hyper-inflammatory conditions that favour mycobacterial growth. Consequently, diverse groups have suggested all patients should have interferon γ release assay (IGRA) testing prior to ICI initiation and there may be merit in serial IGRA

testing before starting immunosuppressive therapies for irAEs.^{43 65 66} The evidence presented here further supports screening of patients for latent Mtb before starting anti-PD-1 treatment and investigation for mycobacterial infection when clinical features are suggestive, especially in high incidence settings. Notably to date, reports of TB primarily centre on the PD-1/PD-L1 axis and there are no cases of CTLA-4 inhibitor monotherapy causing Mtb reactivation.

Hepatitis B Virus

Hepatitis B infected patients were excluded from the initial immunotherapy RCTs. Subsequently, there are multiple reports of hepatitis B reactivation, including cases where immunosuppression has been absent.⁶⁷⁻⁷¹ Furthermore, Burns et al analysed the FAERS database for reported cases of hepatitis B and determined the reporting odds ratio for reactivation with pembrolizumab to be 2.32 (95% CI 1.11-4.28 p=0.013)⁷², thus highlighting elevated risk of viral reactivation with pembrolizumab. Consistent with this, in a retrospective cohort study of 114 cancer patients with a history of hepatitis B who received ICIs, 5.3% developed reactivation of hepatitis B virus.⁷¹ All six patients had undetectable viral DNA at baseline and received PD-1/PD-L1 blockade. Absence of antiviral prophylaxis was the only significant risk factor (OR 17.50 1.95-157.07 p= 0.004). Notably, 12.7% were on concurrent corticosteroids, which were not a significant risk factor, suggesting ICI treatment may have been causative.⁷¹ Additionally, a systematic review of patients with hepatitis B or C revealed that, although ICIs were generally safe, 2.8% showed an increase viral load among 106 patients not on antiviral treatment.⁷³ Furthermore, Lee et al retrospectively reviewed records of 62 patients with hepatitis B related hepatocellular carcinoma. Of the six patients who did not receive antiviral treatment, one developed reactivation of hepatitis B after being treated with nivolumab, while none of the patients who received antiviral therapy developed reactivation of hepatitis B suggesting this may prevent reactivation with ICI.⁷⁴ Notably, viral titres do not appear to be monitored routinely in all centres. One review identified that only six out of 35 patients with hepatitis B/C infection had pre and post treatment viral titres available and did not identify any

reactivation, though it is unclear if these patients were on antiviral therapy.⁷⁵ Another retrospective analysis of nineteen patients with a history of hepatitis B/C revealed only seven patients had viral titre measurement after starting ICI treatment.⁷⁶

Whilst Hepatitis B after ICI treatment can be associated with immunosuppression states,⁶⁹ there is emerging evidence that excess inflammation can also promote viral replication. Immunological assays of chronic hepatitis B virus infected patients have associated high concentrations of PD-1 expressing cytotoxic T lymphocytes with a reduction in acute flares of hepatitis B, while lower number of PD-1 expressing lymphocytes had a higher number of acute flares.⁷⁷ Furthermore, PD-1 expressing lymphocytes were also shown to be functional and secrete interferon- γ , challenging an assumption that these cells are “exhausted”.⁷⁷ Excess cytokine release by blocking PD-1/PD-L1 may result in destruction of hepatocytes, allowing escape of infectious, previously latent virus.⁷⁸

Thus, PD-1 expressing lymphocytes appear to assist with viral control, while blockade of PD-1/PD-L1 signalling and the resulting hyper-inflammatory state may disrupt balanced immune control established in latent hepatitis B infection and promote viral growth. Whilst immunotherapy may be used safely in chronic hepatitis B infection, there is a subset of patients who may develop viral reactivation. Hence appropriate screening and monitoring of hepatitis virus status is vital.

Human Herpesviridae: cytomegalovirus, varicella zoster virus, Epstein-Barr virus

Cytomegalovirus (CMV), *Epstein-Barr virus (EBV)* and *Varicella-zoster virus (VZV)* are herpesviruses that establish a state of chronic latent infection in most humans by adulthood.⁷⁹ Whilst there are a number of reports of CMV following immunosuppression^{33 80 81}, reactivation of CMV^{82 83}, EBV⁸⁴ and VZV^{85 86} in the absence of immunosuppression has also been reported, with features mimicking irAEs.⁸⁷ In fact, some evidence suggests CMV may actually be an underlying trigger for severe irAEs, as CMV is found disproportionately among severe ICI-associated pneumonitis and colitis.^{88 89} A retrospective cohort study analysing checkpoint inhibitor pneumonitis (CIP) revealed that CMV pp65 positivity rate in severe CIP patients was much higher than that in patients without or with mild ICI-

pneumonitis (91.7 vs 20%).⁸⁸ A cohort study by Franklin et al revealed that CMV reactivation was present in all treatment refractory cases through detection of CMV-DNA in biopsy or plasma, or CMV IgM.⁸⁹

Whilst immunosuppression could be the causative factor in some reported cases, the hyper-inflammatory state can promote viral pathology. For example in inflammatory bowel disease, colonic inflammation can impair natural killer cell function, and this along with a damaged mucosa from immunopathology can promote viral reactivation.⁹⁰ This suggests a potential role for dysregulated inflammation in a subset of ICI-associated CMV infection. ICIs may boost virus-specific T cell specific activity,⁹¹ and then inflammation driven by IL-6 and IL-17 may enhance viral persistence by protecting virus-infected cells from apoptosis through expression of Bcl-2 and Bcl-xL^{92 93}. Additionally, in macaques CTLA-4/PD-1 blockade can cause reactivation of SIV.⁹⁴ Overall, these reports argue for a low threshold for investigating for herpesvirus infection before starting immunosuppression for potential irAEs.

Fungal infections

Whilst fungal infection can be a direct consequence of immunosuppression, an emerging number of cases of progressive fungal infection exacerbated by immunotherapy in the absence of immunosuppression are being reported, such as aspergillosis (Figure 4).⁹⁵ Dysregulated immunity appears to play a role, indicated by dramatic worsening of chronic progressive pulmonary aspergillosis and fulminant deterioration of nasal fungal sinusitis post immunotherapy. Again, clinical presentation can mimic cancer progression, with pulmonary cavitation^{95 96}, erosive skull base lesions with bilateral cavernous sinus involvement⁹⁷ and new pulmonary nodules with pleural effusion,^{98 98} and so cases may well be under-reported. In these situations, immune checkpoint blockade may cause an exaggerated immune response to fungal colonisation, which could promote fungal growth similar to recent studies in Mtb infection.⁶⁴

Clostridium difficile

Babacan et al reported 5 cases of *Clostridium difficile* infection (CDI) and irAE colitis, and interestingly 4 of the cases did not have prior exposure to antibiotics and the other case did not have any immunosuppressive treatment.⁹⁹ Additionally, CDI preceding irAE colitis has been reported.^{100 101} Inflammatory bowel disease can present with CDI, even in the absence of immunosuppression,¹⁰² suggesting that excessive inflammation can favour CDI. Given similar pathophysiology in IBD and irAE colitis,¹⁰³ there may be a subset of patients that develop CDI because of the acquired hyper-inflammatory state. Evolving evidence demonstrates that ICIs can alter the gut microbiota, and CDI may be a manifestation of this.¹⁰⁴

Severe acute respiratory syndrome coronavirus 2 (SARS-CoV-2)

In addition to reactivating chronic infections, ICI therapy may worsen acute infections associated with immune asynchrony such as SARS-CoV-2. Cancer patients may have higher risks of severe complications outcomes with SARS-CoV-2 infection regardless of ICI therapy.¹⁰⁵ Interestingly, cancer patients may also have a poor vaccine response, with reduced immunogenicity post a single dose of vaccine.¹⁰⁶ Furthermore, patients with haematological malignancies in particular are at risk of reduced seroconversion, prolonged viral shedding, and sustained immune dysregulation following SARS-CoV-2 infection.¹⁰⁷ These factors make analysis challenging. However, some reports describe rapidly progressive SARS-CoV-2 following ICIs.^{108 109} In a retrospective analysis of 423 cases of cancer patients diagnosed with SARS-CoV-2, ICI use was an independent risk factor for hospitalisation (univariate analysis odds ratio 2.53, 1.18-5.67, p=0.017, multivariate analysis odds ratio 2.84, 1.24-6.72, p= 0.013) and requirement for high flow oxygen support or mechanical ventilation (univariate analysis hazard ratio 2.38, 1.29-4.38, p= 0.005, multivariate analysis hazard ratio 2.38, 1.29-4.38, p= 0.004).¹¹⁰ The risk was different in lung cancer compared to other solid cancers. For lung cancer, 12/23 (52%) patients not on ICIs were hospitalised, 35% developed severe respiratory illness, compared to 10/12 (83%) of lung cancer patients on ICIs, of whom 58% developed severe

respiratory illness. Interestingly only one of 31 ICI-treated patients received corticosteroid therapy prior to SARS-Co-V-2 diagnosis. In contrast, systemic chemotherapy within 30 days was not a risk factor for hospitalisation or severity of illness in this study.¹¹⁰ Another Italian cohort study identified that ICI as well as chemotherapy increased the risk of hospitalisation and death due to SARS-Co-V-2.¹¹¹ Therefore, these series support an adverse interaction between ICIs and SARS-CoV-2 infection, although other studies have not replicated these findings.¹¹²⁻¹¹⁵ Additionally, it has been suggested lung injury induced by SARS Co-V-2 may increase the risk of subsequent irAE pneumonitis.¹¹⁶

In terms of the underlying mechanism, ICI induced immune asynchrony is a potential explanation for more severe COVID-19 infection. Patients with SARS-Co-V-2 infection who are admitted to ICU have higher plasma concentrations of IL-2, IL-6, IL-7, IL-10 and TNF- α and severe SARS-CoV-2 is associated with a cytokine storm.¹¹⁷⁻¹¹⁹ Of note, high concentrations of inflammatory cytokines have predictive potential in irAEs and can also correlate with irAE severity in PD-1 immunotherapy.¹²⁰ Additionally, cytokine release syndrome is a rare complication of PD-1 immunotherapy.¹²¹ Taken together, ICIs could promote a cytokine storm in SARS-CoV-2 via immune dysregulation, increasing the risk of a harmfully excessive response to the pathogen. Recent observations such as the potential benefits of Tocilizumab, an anti IL-6 agent¹²², supports the hypothesis that severe COVID-19 infection is exacerbated by an asynchronous, dysregulated immune state. Clinically it is important to distinguish between SARS-Co-V-2infection and irAE pneumonitis in patients on ICIs.¹²³

Conclusion

ICIs are transformative drugs that improve survival in many forms of cancer, but a common side effect of immunotherapy is immune related adverse events. These irAEs are treated with immunosuppression, which can cause opportunistic infection. However, an emerging paradigm is that ICIs can also lead to a new pattern of infections resulting from dysregulated immunity, which we term Immunotherapy Infections due to Dysregulated Immunity (ITI-DI). Immune checkpoint activity may be necessary for the establishment of latent infection and a stable symbiosis between

352 pathogen and host, and so neutralising these with ICIs may in fact increase infection-related
353 immunopathology (Figure 5).¹²⁴ Screening for chronic infection such as latent TB and hepatitis should
354 be considered before starting ICI therapy, and infection reactivation should be considered within the
355 differential diagnosis even in the absence of immunosuppression.

356

References

1. Burnet M. Cancer: a biological approach. III. Viruses associated with neoplastic conditions. IV. Practical applications. *Br Med J* 1957;1(5023):841-7. doi: 10.1136/bmj.1.5023.841 [published Online First: 1957/04/13]
2. Hanahan D, Weinberg RA. Hallmarks of cancer: the next generation. *Cell* 2011;144(5):646-74. doi: 10.1016/j.cell.2011.02.013 [published Online First: 2011/03/08]
3. Huang P-W, Chang JW-C. Immune checkpoint inhibitors win the 2018 Nobel Prize. *Biomedical Journal* 2019;42(5):299-306. doi: <https://doi.org/10.1016/j.bj.2019.09.002>
4. Ramos-Casals M, Brahmer JR, Callahan MK, et al. Immune-related adverse events of checkpoint inhibitors. *Nature Reviews Disease Primers* 2020;6(1):38. doi: 10.1038/s41572-020-0160-6
5. Martins F, Sofiya L, Sykietis GP, et al. Adverse effects of immune-checkpoint inhibitors: epidemiology, management and surveillance. *Nat Rev Clin Oncol* 2019;16(9):563-80. doi: 10.1038/s41571-019-0218-0 [published Online First: 2019/05/17]
6. Michot JM, Bigenwald C, Champiat S, et al. Immune-related adverse events with immune checkpoint blockade: a comprehensive review. *European Journal of Cancer* 2016;54:139-48. doi: <https://doi.org/10.1016/j.ejca.2015.11.016>
7. Xu C, Chen Y-P, Du X-J, et al. Comparative safety of immune checkpoint inhibitors in cancer: systematic review and network meta-analysis. *BMJ* 2018;363:k4226. doi: 10.1136/bmj.k4226
8. Kanjanapan Y, Day D, Butler MO, et al. Delayed immune-related adverse events in assessment for dose-limiting toxicity in early phase immunotherapy trials. *Eur J Cancer* 2019;107:1-7. doi: 10.1016/j.ejca.2018.10.017 [published Online First: 2018/12/12]
9. Chang HL, Wei PJ, Wu KL, et al. Checkpoint inhibitor pneumonitis mimicking COVID-19 infection during the COVID-19 pandemic. *Lung Cancer* 2020;146:376-77.
10. Tanoue T, Morita S, Plichta DR, et al. A defined commensal consortium elicits CD8 T cells and anti-cancer immunity. *Nature* 2019;565(7741):600-05. doi: 10.1038/s41586-019-0878-z

11. Lo B, Fritz JM, Su HC, et al. CHAI and LATAIE: new genetic diseases of CTLA-4 checkpoint insufficiency. *Blood* 2016;128(8):1037-42. doi: 10.1182/blood-2016-04-712612 [published Online First: 2016/07/14]
12. Gámez-Díaz L, August D, Stepensky P, et al. The extended phenotype of LPS-responsive beige-like anchor protein (LRBA) deficiency. *Journal of Allergy and Clinical Immunology* 2016;137(1):223-30. doi: <https://doi.org/10.1016/j.jaci.2015.09.025>
13. Thye T, Scarisbrick G, Browne EN, et al. CTLA4 autoimmunity-associated genotype contributes to severe pulmonary tuberculosis in an African population. *PLoS One* 2009;4(7):e6307. doi: 10.1371/journal.pone.0006307 [published Online First: 2009/07/18]
14. Barber DL, Mayer-Barber KD, Feng CG, et al. CD4 T cells promote rather than control tuberculosis in the absence of PD-1-mediated inhibition. *J Immunol* 2011;186(3):1598-607. doi: 10.4049/jimmunol.1003304
15. Lazar-Molnar E, Chen B, Sweeney KA, et al. Programmed death-1 (PD-1)-deficient mice are extraordinarily sensitive to tuberculosis. *Proc Natl Acad Sci U S A* 2010;107(30):13402-7. doi: 10.1073/pnas.1007394107
16. Redelman-Sidi G, Michielin O, Cervera C, et al. ESCMID Study Group for Infections in Compromised Hosts (ESGICH) Consensus Document on the safety of targeted and biological therapies: an infectious diseases perspective (Immune checkpoint inhibitors, cell adhesion inhibitors, sphingosine-1-phosphate receptor modulators and proteasome inhibitors). *Clin Microbiol Infect* 2018;24 Suppl 2(Suppl 2):S95-S107. doi: 10.1016/j.cmi.2018.01.030 [published Online First: 2018/02/07]
17. Fujiwara Y, Kuchiba A, Koyama T, et al. Infection risk with PI3K-AKT-mTOR pathway inhibitors and immune checkpoint inhibitors in patients with advanced solid tumours in phase i clinical trials. *ESMO Open* 2020;5(2)
18. Herbst RS, Baas P, Kim DW, et al. Pembrolizumab versus docetaxel for previously treated, PD-L1-positive, advanced non-small-cell lung cancer (KEYNOTE-010): a randomised controlled trial.

408 *Lancet* 2016;387(10027):1540-50. doi: 10.1016/s0140-6736(15)01281-7 [published Online
409 First: 2015/12/30]

410 19. Rizvi NA, Mazières J, Planchard D, et al. Activity and safety of nivolumab, an anti-PD-1 immune
411 checkpoint inhibitor, for patients with advanced, refractory squamous non-small-cell lung
412 cancer (CheckMate 063): a phase 2, single-arm trial. *Lancet Oncol* 2015;16(3):257-65. doi:
413 10.1016/s1470-2045(15)70054-9 [published Online First: 2015/02/24]

414 20. Robert C, Long GV, Brady B, et al. Nivolumab in previously untreated melanoma without BRAF
415 mutation. *N Engl J Med* 2015;372(4):320-30. doi: 10.1056/NEJMoa1412082 [published
416 Online First: 2014/11/18]

417 21. Rosenberg JE, Hoffman-Censits J, Powles T, et al. Atezolizumab in patients with locally advanced
418 and metastatic urothelial carcinoma who have progressed following treatment with
419 platinum-based chemotherapy: a single-arm, multicentre, phase 2 trial. *Lancet*
420 2016;387(10031):1909-20. doi: 10.1016/s0140-6736(16)00561-4 [published Online First:
421 2016/03/10]

422 22. Chou R, Helfand M. Challenges in Systematic Reviews That Assess Treatment Harms. *Annals of*
423 *Internal Medicine* 2005;142(12_Part_2):1090-99. doi: 10.7326/0003-4819-142-12_Part_2-
424 200506211-00009

425 23. Anand K, Ensor J, Trachtenberg B, et al. Osimertinib-Induced Cardiotoxicity. *JACC:*
426 *CardioOncology* 2019;1(2):172-78. doi: doi:10.1016/j.jaccao.2019.10.006

427 24. Del Castillo M, Romero FA, Argüello E, et al. The Spectrum of Serious Infections Among Patients
428 Receiving Immune Checkpoint Blockade for the Treatment of Melanoma. *Clin Infect Dis*
429 2016;63(11):1490-93. doi: 10.1093/cid/ciw539 [published Online First: 2016/08/07]

430 25. Malek AE, Taremi M, Spallone A, et al. Necrotizing soft tissue invasive aspergillosis in a cancer
431 patient treated with immunosuppressants due to checkpoint inhibitor-induced hepatitis. *J*
432 *Infect* 2020;80(2):232-54. doi: 10.1016/j.jinf.2019.10.022 [published Online First:
433 2019/11/11]

26. Gupta A, Tun A, Ticona K, et al. Invasive aspergillosis in a patient with stage III (or 3a or 3b) non-small-cell lung cancer treated with durvalumab. *Case Reports in Oncological Medicine* 2019;2019 (no pagination)
27. Kyi C, Hellmann MD, Wolchok JD, et al. Opportunistic infections in patients treated with immunotherapy for cancer. *Journal for immunotherapy of cancer* 2014;2:19-19. doi: 10.1186/2051-1426-2-19
28. Taima K, Tanaka H, Itoga M, et al. Destroyed lung due to sustained inflammation after chemoradiotherapy followed by durvalumab. *Respirol Case Rep* 2020;8(5):e00580-e80. doi: 10.1002/rcr2.580
29. Arriola E, Wheeler M, Krishnan R, et al. Immunosuppression for ipilimumab-related toxicity can cause pneumocystis pneumonia but spare antitumor immune control. *OncolImmunology* 2015;4(10):e1040218. doi: 10.1080/2162402X.2015.1040218
30. Schwarz M, Kocher F, Niedersuess-Beke D, et al. Immunosuppression for Immune Checkpoint-related Toxicity Can Cause Pneumocystis Jirovecii Pneumonia (PJP) in Non-small-cell Lung Cancer (NSCLC): A Report of 2 Cases. *Clinical Lung Cancer* 2019;20(3):e247-e50.
31. Liu Z, Liu T, Zhang X, et al. Opportunistic infections complicating immunotherapy for non-small cell lung cancer. *Thoracic Cancer* 2020;11(6):1689-94.
32. Martinot M, Ahle G, Petrosyan I, et al. Progressive Multifocal Leukoencephalopathy after Treatment with Nivolumab. *Emerg Infect Dis* 2018;24(8):1594-96. doi: 10.3201/eid2408.180460
33. Furuta Y, Miyamoto H, Naoe H, et al. Cytomegalovirus enterocolitis in a patient with refractory immune-related colitis. *Case Reports in Gastroenterology* 2020;14(1):103-09.
34. Lee KA, Shaw H, Bataille V, et al. Campylobacteriosis following immunosuppression for immune checkpoint inhibitor-related toxicity. *Journal for immunotherapy of cancer* 2020;8(2):e000577. doi: 10.1136/jitc-2020-000577

35. Yang L, Li A, Lei Q, et al. Tumor-intrinsic signaling pathways: key roles in the regulation of the immunosuppressive tumor microenvironment. *Journal of hematology & oncology* 2019;12(1):125-25. doi: 10.1186/s13045-019-0804-8
36. Leung JM, Tiew PY, Mac Aogáin M, et al. The role of acute and chronic respiratory colonization and infections in the pathogenesis of COPD. *Respirology (Carlton, Vic)* 2017;22(4):634-50. doi: 10.1111/resp.13032 [published Online First: 2017/03/25]
37. Fujita K, Kim YH, Kanai O, et al. Emerging concerns of infectious diseases in lung cancer patients receiving immune checkpoint inhibitor therapy. *Respir Med* 2019;146:66-70. doi: 10.1016/j.rmed.2018.11.021 [published Online First: 2019/01/23]
38. Kanjanapan Y, Yip D. Characteristics and risk factors for microbial infections during cancer immune checkpoint therapy. *Cancer Med* 2020 doi: 10.1002/cam4.3532 [published Online First: 2020/11/08]
39. Karam JD, Noel N, Voisin AL, et al. Infectious complications in patients treated with immune checkpoint inhibitors. *Eur J Cancer* 2020;141:137-42. doi: 10.1016/j.ejca.2020.09.025 [published Online First: 2020/11/03]
40. Lee JJX, Chan A, Tang T. Tuberculosis reactivation in a patient receiving anti-programmed death-1 (PD-1) inhibitor for relapsed Hodgkin's lymphoma. *Acta Oncologica* 2016;55(4):519-20. doi: 10.3109/0284186X.2015.1125017
41. Fujita K, Terashima T, Mio T. Anti-PD1 Antibody Treatment and the Development of Acute Pulmonary Tuberculosis. *J Thorac Oncol* 2016;11(12):2238-40. doi: <https://dx.doi.org/10.1016/j.jtho.2016.07.006>
42. Chu YC, Fang KC, Chen HC, et al. Pericardial Tamponade Caused by a Hypersensitivity Response to Tuberculosis Reactivation after Anti-PD-1 Treatment in a Patient with Advanced Pulmonary Adenocarcinoma. *J Thorac Oncol* 2017;12(8):e111-e14. doi: 10.1016/j.jtho.2017.03.012

43. Picchi H, Mateus C, Chouaid C, et al. Infectious complications associated with the use of immune checkpoint inhibitors in oncology: reactivation of tuberculosis after anti PD-1 treatment. *Clinical Microbiology and Infection* 2018;24(3):216-18. doi: <https://doi.org/10.1016/j.cmi.2017.12.003>
44. He W, Zhang X, Li W, et al. Activated pulmonary tuberculosis in a patient with melanoma during PD-1 inhibition: a case report. *Onco Targets Ther* 2018;11:7423-27. doi: 10.2147/OTT.S178246 [published Online First: 2018/11/15]
45. Jensen KH, Persson G, Bondgaard AL, et al. Development of pulmonary tuberculosis following treatment with anti-PD-1 for non-small cell lung cancer. *Acta Oncol* 2018;57(8):1127-28. doi: 10.1080/0284186x.2018.1433877 [published Online First: 2018/02/01]
46. Elkington PT, Bateman AC, Thomas GJ, et al. Implications of Tuberculosis Reactivation after Immune Checkpoint Inhibition. *American Journal of Respiratory and Critical Care Medicine* 2018;198(11):1451-53. doi: 10.1164/rccm.201807-1250LE
47. Tetikkurt S, Taş F, Emre F, et al. Significant Neutrophilic Emperipolesis in Squamous Cell Carcinoma. *Case Reports in Oncological Medicine* 2018;2018:1301562. doi: 10.1155/2018/1301562
48. van Eeden R, Rapoport BL, Smit T, et al. Tuberculosis Infection in a Patient Treated With Nivolumab for Non-small Cell Lung Cancer: Case Report and Literature Review. *Frontiers in Oncology* 2019;9 (no pagination)
49. Barber DL, Sakai S, Kudchadkar RR, et al. Tuberculosis following PD-1 blockade for cancer immunotherapy. *Sci Transl Med* 2019;11(475) doi: 10.1126/scitranslmed.aat2702 [published Online First: 2019/01/18]
50. Takata S, Koh G, Han Y, et al. Paradoxical response in a patient with non-small cell lung cancer who received nivolumab followed by anti-Mycobacterium tuberculosis agents. *J Infect Chemother* 2019;25(1):54-58. doi: 10.1016/j.jiac.2018.06.016 [published Online First: 2018/07/30]

510 51. Crawley D, Breen RA, Elkington PT, et al. Tuberculosis associated with Triplet therapy for lung
511 cancer. *Thorax* 2020;75(7):609-10. doi: 10.1136/thoraxjnl-2019-213913 [published Online
512 First: 2020/05/16]

513 52. Murakami S, Usui R, Nakahara Y, et al. Readministration of Pembrolizumab after Treatment of
514 Tuberculosis Activated by Initial Pembrolizumab Therapy. *Intern Med* 2020 doi:
515 10.2169/internalmedicine.6002-20 [published Online First: 2021/01/05]

516 53. Suliman AM, Bek SA, Elkhatim MS, et al. Tuberculosis following programmed cell death receptor-
517 1 (PD-1) inhibitor in a patient with non-small cell lung cancer. Case report and literature
518 review. *Cancer Immunol Immunother* 2020 doi: 10.1007/s00262-020-02726-1 [published
519 Online First: 2020/10/19]

520 54. Sirgiovanni M, Hinterleitner C, Horger M, et al. Long-term remission of small cell lung cancer
521 after reactivation of tuberculosis following immune-checkpoint blockade: A case report.
522 *Thorac Cancer* 2021;12(5):699-702. doi: 10.1111/1759-7714.13821 [published Online First:
523 2021/01/19]

524 55. Reungwetwattana T, Adjei AA. Anti-PD-1 Antibody Treatment and the Development of Acute
525 Pulmonary Tuberculosis. *J Thorac Oncol* 2016;11(12):2048-50. doi:
526 10.1016/j.jtho.2016.10.008 [published Online First: 2016/11/22]

527 56. Anand K, Sahu G, Burns E, et al. Mycobacterial infections due to PD-1 and PD-L1 checkpoint
528 inhibitors. *ESMO Open* 2020;5(4) doi: 10.1136/esmoopen-2020-000866 [published Online
529 First: 2020/08/21]

530 57. Fujita K, Yamamoto Y, Kanai O, et al. Incidence of Active Tuberculosis in Lung Cancer Patients
531 Receiving Immune Checkpoint Inhibitors. *Open Forum Infect Dis* 2020;7(5):ofaa126. doi:
532 10.1093/ofid/ofaa126 [published Online First: 2020/05/12]

533 58. Alhashimi MM, Citron ML, Fossieck BE, Jr., et al. Lung cancer, tuberculin reactivity, and isoniazid.
534 *South Med J* 1988;81(3):337-40. doi: 10.1097/00007611-198803000-00013 [published
535 Online First: 1988/03/01]

59. Im Y, Lee J, Kim SJ, et al. Development of tuberculosis in cancer patients receiving immune checkpoint inhibitors. *Respir Med* 2020;161:105853. doi: 10.1016/j.rmed.2019.105853 [published Online First: 2020/02/15]
60. Chan GH, Gwee YX, Low JL, et al. Immune checkpoint inhibition for non-small cell lung cancer in patients with pulmonary tuberculosis or Hepatitis B: Experience from a single Asian centre. *Lung Cancer* 2020;146:145-53.
61. Fuentes F, Al-ahwel Y. Emerging Side Effects of Programmed Cell Death 1 Ligand Inhibitors: MAC Infection and Nivolumab. *Chest* 2017;152(4, Supplement):A678. doi: <https://doi.org/10.1016/j.chest.2017.08.708>
62. Fujita K, Yamamoto Y, Kanai O, et al. Development of mycobacterium avium complex lung disease in patients with lung cancer on immune checkpoint inhibitors. *Open Forum Infectious Diseases* 2020;7(3)
63. Tezera LB, Bielecka MK, Ogongo P, et al. Anti-PD-1 immunotherapy leads to tuberculosis reactivation via dysregulation of TNF- α . *Elife* 2020;9:e52668. doi: 10.7554/eLife.52668
64. Kauffman KD, Sakai S, Lora NE, et al. PD-1 blockade exacerbates Mycobacterium tuberculosis infection in rhesus macaques. *Sci Immunol* 2021;6(55) doi: 10.1126/sciimmunol.abf3861 [published Online First: 2021/01/17]
65. Champiat S, Lambotte O, Barreau E, et al. Management of immune checkpoint blockade dysimmune toxicities: a collaborative position paper. *Ann Oncol* 2016;27(4):559-74. doi: 10.1093/annonc/mdv623 [published Online First: 2015/12/31]
66. Langan EA, Graetz V, Allerheiligen J, et al. Immune checkpoint inhibitors and tuberculosis: an old disease in a new context. *The Lancet Oncology* 2020;21(1):e55-e65.
67. Koksas AS, Toka B, Eminler AT, et al. HBV-related acute hepatitis due to immune checkpoint inhibitors in a patient with malignant melanoma. *Ann Oncol* 2017;28(12):3103-04. doi: 10.1093/annonc/mdx502 [published Online First: 2017/09/26]

561 68. Ragunathan K, Dadana S, Huang C-H. Hepatitis B Reactivation After Administration of
562 Pembrolizumab (KEYTRUDA): A Unique Case Report: 2145. *Official journal of the American*
563 *College of Gastroenterology | ACG* 2017;112

564 69. Lake AC. Hepatitis B reactivation in a long-term nonprogressor due to nivolumab therapy. *Aids*
565 2017;31(15):2115-18. doi: 10.1097/qad.0000000000001599 [published Online First:
566 2017/09/15]

567 70. Pandey A, Ezemenari S, Liaukovich M, et al. A Rare Case of Pembrolizumab-Induced Reactivation
568 of Hepatitis B. *Case reports in oncological medicine* 2018;2018:5985131-31. doi:
569 10.1155/2018/5985131

570 71. Zhang X, Zhou Y, Chen C, et al. Hepatitis B virus reactivation in cancer patients with positive
571 Hepatitis B surface antigen undergoing PD-1 inhibition. *Journal for immunotherapy of cancer*
572 2019;7(1):322-22. doi: 10.1186/s40425-019-0808-5

573 72. Burns EA, Muhsen IN, Anand K, et al. Hepatitis B Virus Reactivation in Cancer Patients Treated
574 With Immune Checkpoint Inhibitors. *J Immunother* 2021 doi:
575 10.1097/cji.0000000000000358 [published Online First: 2021/01/23]

576 73. Pu D, Yin L, Zhou Y, et al. Safety and efficacy of immune checkpoint inhibitors in patients with
577 HBV/HCV infection and advanced-stage cancer: A systematic review. *Medicine (Baltimore)*
578 2020;99(5):e19013-e13. doi: 10.1097/MD.00000000000019013

579 74. Lee P-C, Chao Y, Chen M-H, et al. Risk of HBV reactivation in patients with immune checkpoint
580 inhibitor-treated unresectable hepatocellular carcinoma. *Journal for immunotherapy of*
581 *cancer* 2020;8(2):e001072. doi: 10.1136/jitc-2020-001072

582 75. Shah NJ, Al-Shbool G, Blackburn M, et al. Safety and efficacy of immune checkpoint inhibitors
583 (ICIs) in cancer patients with HIV, hepatitis B, or hepatitis C viral infection. *J Immunother*
584 *Cancer* 2019;7(1)

76. Pertejo-Fernandez A, Ricciuti B, Hammond SP, et al. Safety and efficacy of immune checkpoint inhibitors in patients with non-small cell lung cancer and hepatitis B or hepatitis C infection. *Lung Cancer* 2020;145:181-85.
77. Rivino L, Le Bert N, Gill US, et al. Hepatitis B virus-specific T cells associate with viral control upon nucleos(t)ide-analogue therapy discontinuation. *J Clin Invest* 2018;128(2):668-81. doi: 10.1172/jci92812 [published Online First: 2018/01/09]
78. Knolle PA, Thimme R. Hepatic immune regulation and its involvement in viral hepatitis infection. *Gastroenterology* 2014;146(5):1193-207. doi: 10.1053/j.gastro.2013.12.036 [published Online First: 2014/01/15]
79. Pembrey L, Waiblinger D, Griffiths P, et al. Cytomegalovirus, Epstein-Barr virus and varicella zoster virus infection in the first two years of life: a cohort study in Bradford, UK. *BMC Infect Dis* 2017;17(1):220. doi: 10.1186/s12879-017-2319-7 [published Online First: 2017/03/23]
80. Gueguen J, Bailly E, Machet L, et al. CMV disease and colitis in a kidney transplanted patient under pembrolizumab. *European Journal of Cancer* 2019;109:172-74. doi: <https://doi.org/10.1016/j.ejca.2018.12.027>
81. Uslu U, Agaimy A, Hundorfean G, et al. Autoimmune colitis and subsequent CMV-induced hepatitis after treatment with ipilimumab. *Journal of Immunotherapy* 2015;38(5):212-15.
82. Kim H, Ha SY, Kim J, et al. Severe cytomegalovirus gastritis after pembrolizumab in a patient with melanoma. *Curr Oncol* 2020;27(4):e436-e39. doi: 10.3747/co.27.6163 [published Online First: 2020/09/10]
83. Lu J, Firpi-Morell RJ, Dang LH, et al. An Unusual Case of Gastritis in One Patient Receiving PD-1 Blocking Therapy: Coexisting Immune-Related Gastritis and Cytomegaloviral Infection. *Gastroenterology Res* 2018;11(5):383-87. doi: 10.14740/gr1068w [published Online First: 2018/10/01]

84. Saikawa H, Nagashima H, Maeda T, et al. Acute cerebellar ataxia due to Epstein-Barr virus under administration of an immune checkpoint inhibitor. *BMJ Case Reports* 2019;12(12):30. doi: <https://dx.doi.org/10.1136/bcr-2019-231520>
85. Sakoh T, Kanzaki M, Miyamoto A, et al. Ramsay-Hunt syndrome and subsequent sensory neuropathy as potential immune-related adverse events of nivolumab: a case report. *BMC Cancer* 2019;19(1):1220-20. doi: 10.1186/s12885-019-6444-0
86. Assi T, Danu A, Mateus C, et al. Post-shingles granulomatous dermatosis related to anti-programmed cell death 1. *Immunotherapy* 2019;11(7):591-98. doi: 10.2217/imt-2018-0169 [published Online First: 2019/04/05]
87. Lankes K, Hundorfean G, Harrer T, et al. Anti-TNF-refractory colitis after checkpoint inhibitor therapy: Possible role of CMV-mediated immunopathogenesis. *OncolImmunology* 2016;5(6)
88. Lin X, Lu T, Li S, et al. Cytomegalovirus infection as an underestimated trigger for checkpoint inhibitor-related pneumonitis in lung cancer: a retrospective study. *Clinical and Translational Oncology* 2020
89. Franklin C, Rooms I, Fiedler M, et al. Cytomegalovirus reactivation in patients with refractory checkpoint inhibitor-induced colitis. *European Journal of Cancer* 2017;86:248-56.
90. Lawlor G, Moss AC. Cytomegalovirus in inflammatory bowel disease: pathogen or innocent bystander? *Inflammatory bowel diseases* 2010;16(9):1620-27.
91. Johnson DB, McDonnell WJ, Gonzalez-Ericsson PI, et al. A case report of clonal EBV-like memory CD4⁺ T cell activation in fatal checkpoint inhibitor-induced encephalitis. *Nature Medicine* 2019;25(8):1243-50.
92. Davis BK, Wen H, Ting JPY. The inflammasome NLRs in immunity, inflammation, and associated diseases. *Annual review of immunology* 2011;29:707-35. doi: 10.1146/annurev-immunol-031210-101405

93. Hou W, Jin Y-H, Kang HS, et al. Interleukin-6 (IL-6) and IL-17 synergistically promote viral persistence by inhibiting cellular apoptosis and cytotoxic T cell function. *Journal of virology* 2014;88(15):8479-89. doi: 10.1128/JVI.00724-14 [published Online First: 2014/05/14]
94. Harper J, Gordon S, Chan CN, et al. CTLA-4 and PD-1 dual blockade induces SIV reactivation without control of rebound after antiretroviral therapy interruption. *Nat Med* 2020;26(4):519-28. doi: 10.1038/s41591-020-0782-y [published Online First: 2020/04/15]
95. Inthasot V, Bruyneel M, Muylle I, et al. Severe pulmonary infections complicating nivolumab treatment for lung cancer: a report of two cases. *Acta Clin Belg* 2020;75(4):308-10. doi: 10.1080/17843286.2019.1629078 [published Online First: 2019/06/11]
96. Uchida N, Fujita K, Nakatani K, et al. Acute progression of aspergillosis in a patient with lung cancer receiving nivolumab. *Respirol Case Rep* 2017;6(2):e00289-e89. doi: 10.1002/rcr2.289
97. Krane NA, Beswick DM, Sauer D, et al. Allergic Fungal Sinusitis Imitating an Aggressive Skull Base Lesion in the Setting of Pembrolizumab Immunotherapy. *Ann Otol Rhinol Laryngol* 2020;3489420937728. doi: 10.1177/0003489420937728 [published Online First: 2020/07/01]
98. Ferguson I, Heberton M, Compton L, et al. Disseminated blastomycosis in a patient on pembrolizumab for metastatic melanoma. *JAAD Case Rep* 2019;5(7):580-81. doi: 10.1016/j.jdc.2019.05.001
99. Babacan NA, Tanvetyanon T. Superimposed Clostridium difficile Infection during Checkpoint Inhibitor Immunotherapy-induced Colitis. *Journal of Immunotherapy* 2019;42(9):350-53.
100. Zhou C, Klionsky Y, Treasure ME, et al. Pembrolizumab-Induced Immune-Mediated Colitis in a Patient with Concurrent Clostridium Difficile Infection. *Case Reports in Oncology* 2019;12(1):164-70.
101. Gupta A, Khanna S. Ipilimumab-associated colitis or refractory Clostridium difficile infection? *BMJ Case Rep* 2015;2015 doi: 10.1136/bcr-2015-211160 [published Online First: 2015/07/15]

102. Singh H, Nugent Z, Yu BN, et al. Higher Incidence of Clostridium difficile Infection Among Individuals With Inflammatory Bowel Disease. *Gastroenterology* 2017;153(2):430-38.e2. doi: 10.1053/j.gastro.2017.04.044 [published Online First: 2017/05/10]
103. Lo YC, Price C, Blenman K, et al. Checkpoint Inhibitor Colitis Shows Drug-Specific Differences in Immune Cell Reaction That Overlap With Inflammatory Bowel Disease and Predict Response to Colitis Therapy. *Am J Clin Pathol* 2021 doi: 10.1093/ajcp/aqaa217 [published Online First: 2021/02/09]
104. Abu-Sbeih H, Wang Y. Gut Microbiome and Immune Checkpoint Inhibitor-Induced Enterocolitis. *Dig Dis Sci* 2020;65(3):797-99. doi: 10.1007/s10620-020-06103-x [published Online First: 2020/02/11]
105. Dai M, Liu D, Liu M, et al. Patients with Cancer Appear More Vulnerable to SARS-CoV-2: A Multicenter Study during the COVID-19 Outbreak. *Cancer Discov* 2020;10(6):783-91. doi: 10.1158/2159-8290.Cd-20-0422 [published Online First: 2020/04/30]
106. Palich R, Veyri M, Marot S, et al. Weak immunogenicity after a single dose of SARS-CoV-2 mRNA vaccine in treated cancer patients. *Annals of oncology : official journal of the European Society for Medical Oncology* 2021:S0923-7534(21)01184-4. doi: 10.1016/j.annonc.2021.04.020
107. Abdul-Jawad S, Baù L, Alaguthurai T, et al. Acute Immune Signatures and Their Legacies in Severe Acute Respiratory Syndrome Coronavirus-2 Infected Cancer Patients. *Cancer Cell* 2021;39(2):257-75.e6. doi: 10.1016/j.ccell.2021.01.001 [published Online First: 2021/01/05]
108. Bonomi L, Ghilardi L, Arnoldi E, et al. A Rapid Fatal Evolution of Coronavirus Disease-19 in a Patient With Advanced Lung Cancer With a Long-Time Response to Nivolumab. *Journal of thoracic oncology : official publication of the International Association for the Study of Lung Cancer* 2020;15(6):e83-e85. doi: 10.1016/j.jtho.2020.03.021 [published Online First: 2020/03/31]

109. Zhai M, Zhang S. A Nasopharyngeal Carcinoma Patient With COVID-19 Infection After Immunotherapy: A Case Report and Literature Review. *In Vivo* 2020;34(6):3753-56. doi: 10.21873/invivo.12225 [published Online First: 2020/11/05]
110. Robilotti EV, Babady NE, Mead PA, et al. Determinants of COVID-19 disease severity in patients with cancer. *Nature Medicine* 2020;26(8):1218-23. doi: 10.1038/s41591-020-0979-0
111. Mandala M, Lorigan P, De Luca M, et al. SARS-CoV-2 infection and adverse events in patients with cancer receiving immune checkpoint inhibitors: an observational prospective study. *Journal for immunotherapy of cancer* 2021;9(2):e001694. doi: 10.1136/jitc-2020-001694
112. Luo J, Rizvi H, Egger JV, et al. Impact of PD-1 Blockade on Severity of COVID-19 in Patients with Lung Cancers. *Cancer Discovery* 2020;10(8):1121. doi: 10.1158/2159-8290.CD-20-0596
113. Yekedüz E, Utkan G, Ürün Y. A systematic review and meta-analysis: the effect of active cancer treatment on severity of COVID-19. *Eur J Cancer* 2020;141:92-104. doi: 10.1016/j.ejca.2020.09.028 [published Online First: 2020/11/02]
114. Pala L, Conforti F, Cocorocchio E, et al. Course of Sars-CoV2 Infection in Patients with Cancer Treated with anti-PD-1: A Case Presentation and Review of the Literature. *Cancer Invest* 2021;39(1):9-14. doi: 10.1080/07357907.2020.1844893 [published Online First: 2020/10/31]
115. Szabados B, Abu-Ghanem Y, Grant M, et al. Clinical Characteristics and Outcome for Four SARS-CoV-2-infected Cancer Patients Treated with Immune Checkpoint Inhibitors. *European Urology* 2020;78(2):276-80.
116. Dipasquale A, Persico P, Lorenzi E, et al. COVID-19 lung injury as a primer for immune checkpoint inhibitors (ICIs)-related pneumonia in a patient affected by squamous head and neck carcinoma treated with PD-L1 blockade: a case report. *J Immunother Cancer* 2021;9(2) doi: 10.1136/jitc-2020-001870 [published Online First: 2021/02/13]
117. Zhao D, Yao F, Wang L, et al. A Comparative Study on the Clinical Features of Coronavirus 2019 (COVID-19) Pneumonia With Other Pneumonias. *Clin Infect Dis* 2020;71(15):756-61. doi: 10.1093/cid/ciaa247 [published Online First: 2020/03/13]

118. Huang C, Wang Y, Li X, et al. Clinical features of patients infected with 2019 novel coronavirus in Wuhan, China. *Lancet* 2020;395(10223):497-506. doi: 10.1016/S0140-6736(20)30183-5 [published Online First: 2020/01/24]
119. Mehta P, McAuley DF, Brown M, et al. COVID-19: consider cytokine storm syndromes and immunosuppression. *Lancet* 2020;395(10229):1033-34. doi: 10.1016/s0140-6736(20)30628-0 [published Online First: 2020/03/21]
120. Lim SY, Lee JH, Gide TN, et al. Circulating Cytokines Predict Immune-Related Toxicity in Melanoma Patients Receiving Anti-PD-1-Based Immunotherapy. *Clin Cancer Res* 2019;25(5):1557-63. doi: 10.1158/1078-0432.Ccr-18-2795 [published Online First: 2018/11/10]
121. Rotz SJ, Leino D, Szabo S, et al. Severe cytokine release syndrome in a patient receiving PD-1-directed therapy. *Pediatr Blood Cancer* 2017;64(12) doi: 10.1002/pbc.26642 [published Online First: 2017/05/26]
122. Antony SJ, Davis MA, Davis MG, et al. Early use of tocilizumab in the prevention of adult respiratory failure in SARS-CoV-2 infections and the utilization of interleukin-6 levels in the management. *J Med Virol* 2021;93(1):491-98. doi: 10.1002/jmv.26288 [published Online First: 2020/07/10]
123. Dai Y, Liu S, Zhang Y, et al. A false alarm of COVID-19 pneumonia in lung cancer with anti-PD-1 related pneumonitis: a case report and review of the literature. *J Med Case Rep* 2021;15(1):41. doi: 10.1186/s13256-020-02619-y [published Online First: 2021/02/02]
124. Cai H, Liu G, Zhong J, et al. Immune Checkpoints in Viral Infections. *Viruses* 2020;12(9):1051. doi: 10.3390/v12091051

734 **Table 1: ImmunoTherapy Infections due to ImmunoSuppression (ITI-IS)**

735

Authors	Study Types	ICI class	Immunosuppressive Agents	Pathogen
(Arriola, Wheeler et al. 2015, Del Castillo, Romero et al. 2016, Schwarz, Kocher et al. 2019, Liu, Liu et al. 2020, Si, Erickson et al. 2020)	Case report, Cohort	CTLA-4, PD-1, PD-L1	Corticosteroids, TNF- α antagonists, Mycophenolate mofetil	<i>Pneumocystis jirovecii</i>
(Lord, Hackman et al. 2010, Kyi, Hellmann et al. 2014, Del Castillo, Romero et al. 2016, Gupta, Tun et al. 2019, Oltolini, Ripa et al. 2019, Liu, Liu et al. 2020, Malek, Taremi et al. 2020, Taima, Tanaka et al. 2020)	Case report, cohort	CTLA-4, PD-1, PD-L1	Corticosteroids, TNF- α antagonists, Rituximab, Mycophenolate Mofetil, Tacrolimus, Rapamycin	<i>Aspergillus fumigatus</i>
(Del Castillo, Romero et al. 2016, Liu, Liu et al. 2020)	Case report, Cohort	CTLA-4, PD-1, PD-L1	Corticosteroids, TNF- α antagonists	<i>Candida albicans</i>
(Uslu, Agaimy et al. 2015, Del Castillo, Romero et al. 2016, Oltolini, Ripa et al. 2019, Schwarz, Kocher et al. 2019, Liu, Liu et al. 2020)	Case report, Cohort	CTLA-4, PD-1	Corticosteroids, TNF- α antagonists, Mycophenolate mofetil	<i>Cytomegalovirus</i>
(Martinot, Ahle et al. 2018)	Case report, unpublished pharmacovigilance registry data (WHO and Eudra-Vigilance)	CTLA-4 (PD-1 registry data)	Corticosteroids	<i>JC polyoma virus</i>
(Del Castillo, Romero et al. 2016, Oltolini, Ripa et al. 2019, Lee, Shaw et al. 2020, Liu, Liu et al. 2020)	Case report, Cohort	CTLA-4, PD-1, PD-L1	Corticosteroids, TNF- α antagonists	Other bacterial: including non specified organism, bacteraemic sepsis , <i>Pseudomonas aeruginosa</i> , <i>Stenotrophomonas maltophilia</i> , <i>Corynebacterium striatu</i> , <i>Campylobacter</i>

736

Figure legends

Figure 1: PRISMA chart

Figure 2: Spectrum of Immunotherapy associated infections. Whilst immunosuppression alone can cause infectious complications, the dysregulated immunity that results from immune checkpoint inhibition can lead to different patterns of infection reactivation due to excessive inflammation, thereby resulting in a spectrum of disease phenotypes.

Figure 3: Development of pulmonary TB on Triplet chemotherapy. Comparison of diagnostic CT scan performed 2 weeks before treatment (A) with the CT scan at time of TB diagnosis (B) shows regression of the tumour with immune checkpoint inhibition but new consolidation with cavitation.

Figure 4: Development of pulmonary aspergillus infection on nivolumab treatment. Original publication: Inthasot et al (2020) *Acta Clinica Belgica*, 75:4, 308-310, Reproduced with permission of publisher.

Figure 5: Potential Mechanisms whereby ICIs may lead to reactivation of infection and immune-related tissue damage. Sustained antigen exposure from persistently infected cells can cause an over-exuberant immune response harmful to the host. Immune Checkpoints (IC) may regulate homeostasis in latent infection, while signalling disruption with ICIs may promote excessive inflammation, infection reactivation and immunopathology.

PRISMA 2009 Flow Diagram

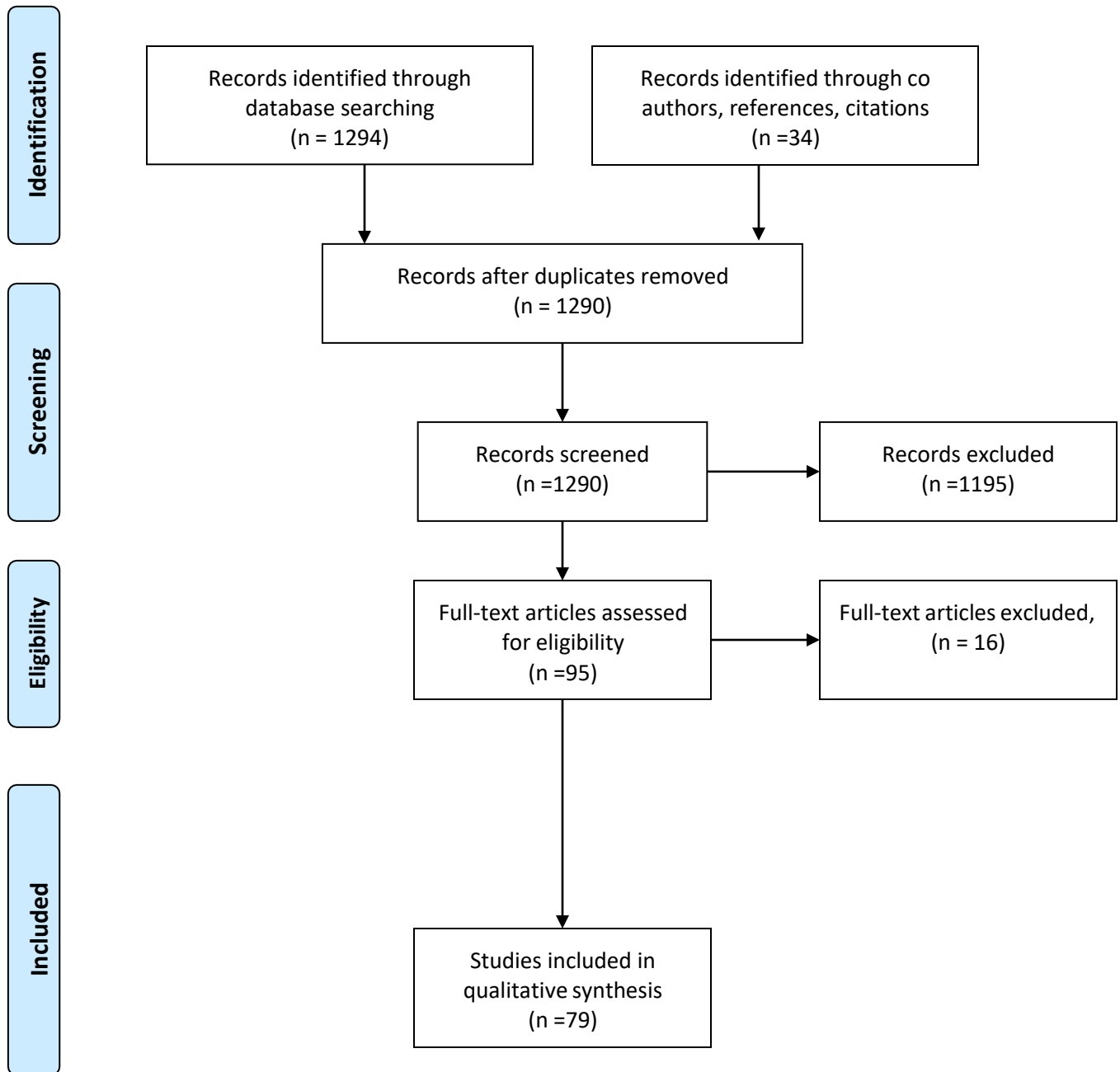


Figure 1: PRISMA chart



Immunosuppression
ITI-IS

Dysregulated immunity
ITI-DI

