

# International Journal of Paleopathology

## Which types of bony changes in the maxillary sinus indicate chronic sinusitis?

--Manuscript Draft--

<b>Manuscript Number:</b>	IJP-D-23-00086R3
<b>Article Type:</b>	Research Article
<b>Keywords:</b>	Spicules; porosity; dental disease; odontogenic
<b>Corresponding Author:</b>	Simon Mays Historic England portsmouth, UNITED KINGDOM
<b>First Author:</b>	Simon Mays
<b>Order of Authors:</b>	Simon Mays Sarah Stark Sonia Zakrzewski Anna Vekony
<b>Abstract:</b>	<p><b>Objectives.</b> To determine which types of bone lesion (spicules, lobules, porous bone) in the maxillary sinus indicate sinusitis</p> <p><b>Methods.</b> Subadjacent dental disease is a cause of maxillary sinusitis; if a lesion type indicates sinusitis it should be more common above diseased posterior maxillary teeth than a lesion type that is not indicative of sinusitis. The study sample is a British Mediaeval human skeletal collection.</p> <p><b>Results.</b> Porous bone lesions (chiefly new bone deposits) in maxillary sinuses are associated with subadjacent dental disease; spicules/lobules of bone in the sinus are not.</p> <p><b>Conclusions.</b> The results support the idea that porous lesions indicate sinusitis but the spicules/lobules may not. Spicules, lobules and porous lesions within the maxillary sinus should be analysed separately in biocultural studies; it would be prudent to regard only the porous lesions as indicative of sinusitis.</p> <p><b>Significance.</b> Maxillary sinusitis is commonly used as a health indicator in palaeopathology, and spicular deposits are generally the most common type of alterations. By assuming that they are indicative of sinusitis we may have been greatly overestimating the prevalence of bony sinusitis in the past.</p> <p><b>Limitations.</b> These conclusions are provisional. Further work on larger, more diverse samples, together with more detailed anatomical studies on lesion location and structure is ongoing.</p>
<b>Suggested Reviewers:</b>	Charlotte Roberts Anna Davies Barrett Mary Lewis
<b>Opposed Reviewers:</b>	
<b>Response to Reviewers:</b>	

Reviewer #1: Many thanks to the authors for considering and incorporating most of the comments I added in the previous round of review. In my opinion, this paper will be a great add to our current knowledge on sinusitis.

**RESPONSE:** Thank-you for these remarks.

Reviewer #3: I would like to thank the authors in further investigating methodology in sinusitis diagnoses in paleopathology. I also commend them on applying the recommendations of the previous reviewers as it has resulted in a robust study of the subject matter. As such, at this point, I have only a few minor comments regarding grammar and format:

\* On page 3, at the start of the Materials section, I suggest noting the time period as CE rather than AD, following modern conventions.

**RESPONSE:** change made.

\* In the Methods section, I think the paragraph at the end of page 4 regarding the odontogenic cause of sinusitis should be moved to the introduction section, as this paragraph does not outline methodology used in the paper, but does give necessary background.

**RESPONSE:** I appreciate why the reviewer feels that this para fits better in the intro, but it is part of building an argument for the methodology used in the paper. If we were to put it in the intro it would not fit well with the other paragraphs in that section, which set out the general background whereas this goes into quite a bit of detail on one particular area of work. We would also need to refer back to it in the methods section so that a reader could understand why we are concentrating on the specific types of dental disease that we are, especially AMTL whose connection with sinusitis is not immediately obvious and requires close explanation (as illustrated by previous remarks of reviewres who questioned the use of this variable in our work). On balance therefore I think it makes more sense to leave this paragraph where it is.

\* On page 8, at the start of the Discussion section, the first paragraph should be joined with the second as they are concerned with the same subject and points of discussion

**RESPONSE:** change made.

\* I recommend capitalizing all abbreviations used throughout the manuscript, such as "amtl", for ease of use on the part of the reader.

**RESPONSE:** change made.

## Which types of bony changes in the maxillary sinus indicate chronic sinusitis?

S. Mays<sup>1,2,3</sup>, S. Stark<sup>1,2</sup>, S. Zakrzewski<sup>2</sup>, A. Vekony<sup>2</sup>

<sup>1</sup>Investigative Science, Historic England, UK <sup>2</sup>Department of Archaeology, University of Southampton, UK <sup>3</sup>School of History, Classics and Archaeology, University of Edinburgh, UK

### Abstract

**Objectives.** To determine which types of bone lesion (spicules, lobules, porous bone) in the maxillary sinus indicate sinusitis

**Methods.** Subadjacent dental disease is a cause of maxillary sinusitis; if a lesion type indicates sinusitis it should be more common above diseased posterior maxillary teeth than a lesion type that is not indicative of sinusitis. The study sample is a British Mediaeval human skeletal collection.

**Results.** Porous bone lesions (chiefly new bone deposits) in maxillary sinuses are associated with subadjacent dental disease; spicules/lobules of bone in the sinus are not.

**Conclusions.** The results support the idea that porous lesions indicate sinusitis but the spicules/lobules may not. Spicules, lobules and porous lesions within the maxillary sinus should be analysed separately in biocultural studies; it would be prudent to regard only the porous lesions as indicative of sinusitis.

**Significance.** Maxillary sinusitis is commonly used as a health indicator in palaeopathology, and spicular deposits are generally the most common type of alterations. By assuming that they are indicative of sinusitis we may have been greatly overestimating the prevalence of bony sinusitis in the past.

**Limitations.** These conclusions are provisional. Further work on larger, more diverse samples, together with more detailed anatomical studies on lesion location and structure is ongoing.

### Keywords

Spicules; porosity; dental disease; odontogenic

### 1. Introduction

Rhinosinusitis<sup>1</sup> is inflammation involving the mucosal lining of one or more of the paranasal sinuses. Chronic rhinosinusitis (CRS), defined as disease of at least 12 weeks duration, is today a highly prevalent condition with significant socioeconomic impacts (Fokkens et al., 2020). In the maxillary sinuses, some CRS may be odontogenic in origin, with infection in the subadjacent posterior maxillary tooth row being transmitted via the floor of the sinus (Vidal et al., 2017). Despite this, most cases are rhinogenic (Martu et al., 2022): that is, transmitted via the nasal airways. There are multiple risk factors for CRS, but studies have consistently demonstrated a link with aerial pollutants, especially particulates (Leland et al., 2022).

---

<sup>1</sup> 'Rhinosinusitis' is the preferred term over 'sinusitis' in biomedicine given the mucosal continuity between the paranasal sinuses and the nasal cavity proper (Ferguson, 2014). Here we only use 'sinusitis' when we refer specifically to alterations within the sinus itself.

A key imaging finding in rhinosinusitis in patients is thickening of the mucosal lining of the sinuses (Momeni et al., 2007; Mafee et al., 2016). It has been known for some time that thickening of the bony sinus wall, by deposition of new bone upon its internal surface, may also occur in CRS (e.g. Buchner & Lessel, 1978 & refs therein). Recent work using study groups of large sample size suggests that bone changes sufficient to be visible on CT in one or more of the paranasal sinuses may be rather frequent among individuals showing CRS. Lee et al. (2006) report a prevalence of 36% (N=121 cases of CRS; maxillary, sphenoid, ethmoid sinuses examined); 16% showed alterations specifically in the maxillary sinuses. Studies by Kim et al. (2006) and Georgalas et al. (2010) each report prevalences of 64%: in the former N=81, maxillary and ethmoid sinuses and middle turbinates assessed; in the latter N=102, all 10 sinuses evaluated. Snidvongs et al. (2012, 2013) found a prevalence of 51% (N=88, all 10 sinuses assessed). Bony alteration is associated with increased severity of mucosal inflammation (Telmesani & Al-Shawarby, 2010; Bhandarkar et al., 2011) and with increased duration of disease (Georgalas et al., 2010).

For more than 60 years, palaeopathologists have taken the presence of new bone on the internal surfaces of the paranasal sinuses as an indicator of CRS (e.g. Roney, 1959; Wells, 1977; Suzuki et al. 1983). The focus of study in skeletal remains has almost exclusively been the maxillary sinuses, as they are the largest and most readily accessible of the paranasal sinuses. The link between CRS and atmospheric pollution has led to the use of maxillary sinusitis in palaeopathology as an index of air quality in the past. Quantitative, population-based, biocultural studies of maxillary sinusitis have been undertaken to investigate the effects on access to adequate air quality of urbanisation (Lewis et al., 1995; Panhuysen et al., 1997; Bernofsky, 2010; Sundman & Kjellström, 2013a,b; Boyd, 2020; Krenz-Niedbala & Łukasik, 2020; Casna et al., 2021, 2023), socio-economic status (Digangi & Siriani, 2017; Casna & Schrader, 2022), industrialisation (Buckberry & Crane-Kramer, 2022), and general living conditions (Wells, 1977; Gregg & Gregg, 1987; Cybulski, 1988; Brothwell & Browne, 1994; Merrett & Pfeiffer, 2000; Liebe-Harkort, 2012; Teul et al., 2013; Magalhães, 2018; Mahoney-Swales, 2018; Davies-Barrett et al., 2021a,b; Riccomi et al., 2021). There have also been investigations of links between CRS and other upper respiratory problems, such as nasal obstruction (Mays et al., 2014; Magalhães et al., 2017); systemic infectious conditions with nasal involvement, such as leprosy (Boocock et al., 1995); lower respiratory infections, as indicated by periosteal lesions of costal elements (Bernofsky, 2010); and middle ear disease (Collins, 2018).

The normal internal surfaces of the maxillary bony sinus are of compact bone. They are generally fairly smooth, with some perforations and channels for small nerves and blood vessels; the floor of the sinus may be rather irregular, reflecting the profile of the root tips of the underlying dentition (Boocock et al., 1995; Lewis et al., 1995; Sundman & Kjellström, 2013a). Bone abnormalities recorded in the maxillary sinuses generally take the form of spicular projections or rounded 'lobules' of bone, or else finely or more coarsely / irregularly porous bone. Although the spicules / lobules may show some porosity on their surfaces, this is generally not marked, and they have compact bone surfaces. These basic types were described nearly 30 years ago by Boocock et al. (1995), a publication that has been influential in palaeopathology (Lee et al., 2024). However, for purposes of analysis in biocultural studies, the different types of alterations are commonly combined to give an overall prevalence of maxillary sinusitis.

In the skeleton, inflammation, which may arise due to infection, may elicit new bone formation beneath the periosteum. This generally takes the form of one or more layers of new bone upon an extant cortical surface (Resnick, 1995: 4435; Wenaden et al., 2005; Allen et al., 2023). Initially, deposits take the form of woven bone. Grossly, this appears as a discrete lens of bone with sharply

demarcated edges. It has a finely porous surface, reflecting the loose organisation of the mineralised osteoid fibres and the abundant vascularisation. As a deposit remodels, and the bone becomes more organised and the vascular channels fewer, the surface loses its finely porous nature and progressively assumes a more coarsely porous appearance. The bony texture gradually becomes more corticated and the lesion-edges begin to blend more smoothly with the surrounding cortex (Ortner, 2008; Weston, 2008). Porous new bone deposits observed in the maxillary sinuses appear to morphologically resemble this type of bone elicited in response to inflammation produced by infection elsewhere in the skeleton. Finely porous new bone observed in the sinus probably represents less remodelled, and the more coarsely porous deposits more thoroughly remodelled lesions. However, the lobules, and especially the spicular forms of bone deposition, are morphologically rather different. This raises the possibility that they might arise via some process other than inflammation in the sinus, and hence that the interpretation of their presence as indicative of CRS may be erroneous. This possibility has been raised previously (Mays et al., 2014; Davies-Barrett et al., 2021b), but has not, to our knowledge, been systematically investigated. This is an important problem because spicular deposits are generally the most frequent bone alterations seen in the maxillary sinus in skeletal collections (e.g. Boocock et al., 1995; Lewis et al., 1995; Bonofsky, 2010; Sundman & Kjellström, 2013a; Riccomi et al., 2021). If we are in error in considering these, and the apparently rarer lobules, as indicators of sinusitis, then our estimates of prevalences of bony maxillary sinusitis in past populations would be greatly inflated. For example, using data in Davies-Barrett et al. (2021b) and in Teul et al. (2013), omitting spicules and lobules reduces the prevalence of maxillary sinusitis among their ancient Peruvian and Polish samples from 94% to 19% and 75% to 33% respectively.

The clinical imaging literature generally refers to hyperostotic changes in CRS in terms of thickening of maxillary sinus walls (e.g. Buchner & Lessel, 1978; Tovi et al., 1992; Kim et al., 2006; Lee et al., 2006; Georgalas et al., 2010; Snidvongs et al., 2012). It is of little assistance in resolving the precise morphology of bony deposits (lobular, spicular, porous). Rather than attempt to make comparisons with clinical images, it may be more useful to take an indirect approach in order to investigate whether these different types of alterations are linked with sinusitis in ancient remains. As mentioned above, dental disease in the maxilla is a potential cause of sinusitis. Clearly, infection in the underlying maxillary tooth row does not invariably lead to sinusitis, and conversely, sinusitis may occur in its absence due to rhinogenic causes. Nevertheless, because of the potential for maxillary sinusitis to arise due to direct extension from maxillary odontological infection, a lesion type within a maxillary sinus that is indicative of sinusitis should be more frequent above diseased tooth sockets than a lesion type that is not indicative of sinusitis. Our study is based on this premise.

## **2. Materials and methods**

The study material comes from the deserted village of Wharram Percy, England. The remains date primarily from the 11<sup>th</sup>-14<sup>th</sup> century CE (Mays, 2007). This collection was chosen for the current work for several reasons. It is of large size (N=360 adults). The remains were macroscopically well preserved, but the facial bones were fragmented, facilitating observations of internal maxillary sinus walls. Previous works (Lewis et al., 1995; Mays et al., 2014) indicated a prevalence of sinus alterations (51% and 58% respectively in adults) sufficient to provide a workable sample.

Entry criteria for the current study were that the individual be adult (ca. 18+ yrs) and had at least one maxillary sinus zone (see below) present for observation. All recordings were undertaken macroscopically. No endoscopy was performed, so fully intact sinuses were not investigated. A total

of 119 left and 121 right maxillary sinuses from 133 individuals were studied (107 individuals preserved both sinuses, 26 preserved only one).

Each maxillary sinus was divided into three anatomical zones, corresponding to the inferior, medial and lateral walls (Fig. 1). A zone was considered to be available for observation if at least 50% of it was present. Lesions in the roof of the sinus were not studied because this region was rarely preserved. In each zone, alterations were recorded as shown in Table 1, and illustrated in Figure 2.

Table 1. Observations on internal sinus walls

Code	Description
-	Zone missing (i.e. unobservable)
0	No lesions
1	Spicules
2	Lobules
3	Fine porosity
4	Coarse porosity

The classification in Table 1 was adapted from that of Boocock et al. (1995). Lobules and spicules follow their descriptions, although for the latter no attempt was made to distinguish their 'spicule' and 'remodelled spicule' categories. For porous lesions, we divided our lesions into fine and coarse porosity; the reason for this was that we felt that this was likely to correspond to degrees of remodelling in instances where porosity was due to deposits of new bone within the sinus. Fine porosity consisted of closely spaced, fine pores (Fig. 2d). Lesions classified as coarse porosity showed pores that were larger, generally more variable in size, and more widely spaced (Fig. 2e). Where either fine or coarse porosity was observed, the extent to which it reflected new bone formation versus porosity of existing bone was evaluated by studying closely the margins of lesions in order to determine whether they were elevated with respect to the surrounding bone, which would be suggestive of bone formation. If more than one type of bone alteration was present in a single zone, the predominant type was entered on the record sheet, but a note was made of the subsidiary type(s). The presence of any oro-antral fistulae (Sundmann & Kjellström, 2013a: Fig. 3) was also noted. All burials were recorded by a single observer (AV). Twenty-nine individuals, yielding 54 sinuses, selected at random were re-recorded, at an interval of two weeks, to investigate intraobserver error in the recording of sinus lesions.

Today, the most frequent odontogenic cause of maxillary sinusitis is iatrogenic: inadvertent perforation of the sinus floor during dental surgery (Lechien et al., 2014). In non-iatrogenic cases, it occurs as contiguous infection from the subadjacent tooth row, the mechanisms of which were elucidated in a classic study of cadaver preparations by William Bauer (Bauer, 1943). That work demonstrated that no direct connection between oral cavity and maxillary sinus (in the form of a fistula) was required. Odontogenic infection from the apical area of a tooth root is transmissible, via the dense network of blood vessels and lymphatic tissue in the bony floor of the antrum, to the mucosal lining of the sinus. In instances where this had occurred, inflammation of the mucosa lining on the sinus floor was observed, but a localised bony reaction was also sometimes evident. In the subadjacent posterior maxillary dentition, both periapical infections from root canal disease and deep gingival pockets could potentially lead to sinus infections. Subsequent studies confirm that, aside from iatrogenic causes, periapical infections resulting from tooth root canal disease (Shanbhag et al., 2013; Sheikhi et al., 2014; Troeltsche et al., 2015; Nunes et al., 2016; Sakir & Yalcinkaya, 2020;

Curi et al., 2020; Dumitrescu et al., 2021; Kuligowski et al., 2021; Huang et al., 2021) and advanced periodontitis, particularly with formation of deep periodontal pockets (Sheikhi et al., 2014; Ren et al., 2015; Troeltzsche et al., 2015; Aksoy & Orhan, 2019; Lathiya et al., 2019; Curi et al., 2020; Kuligowski et al., 2021; Huang et al., 2021; Bisla et al., 2022) are the chief causes of odontogenic maxillary sinusitis.

As noted above, it is advanced periodontitis that is associated with maxillary sinus disease. Degradation of the periodontal ligament and loss of alveolar bone characteristic of advanced periodontal disease result in loss of support for the dentition. Advanced periodontal disease is a leading cause of tooth loss today (Darveau, 2010; Hajishengallis et al., 2020; Balta et al., 2021). In skeletal populations, *ante mortem* tooth loss (AMTL) is multifactorial, with factors such as super-eruption of teeth in high attrition environments (Clarke & Hirsch, 1991) and perhaps, on occasion, extraction of painful teeth (Kerr 1998) being likely contributors. However, as today, advanced periodontal disease was likely a major cause (Ogden, 2008; Larsen, 2015: 81). Whilst we are mindful of the multicausal nature of AMTL, in the light of the above discussion, we use AMTL as a marker of the probable presence of previous advanced periodontal disease and hence of the previous existence of deep periodontal pockets or (probably to a lesser extent) periapical lesions consequential upon root canal infection due to advanced caries or advanced attrition.

The maxillary sinus normally lies above the post-canine dentition (Hauman et al., 2002). Maxillary sinuses above first premolar to third molar tooth sockets with one or more periapical voids and/or one or more tooth positions showing AMTL (hereafter denoted 'diseased' tooth rows) were distinguished from those above tooth rows that did not show these particular pathologies (hereafter denoted 'healthy' tooth rows). These dental pathologies, and age at death and sex of the individuals, were recorded as previously described (Mays 2007: 85, 133). For any class of sinus alteration (porous versus spicules / lobules) that proved to be statistically associated with diseased tooth rows, closer anatomical study was made of the nature and location of changes within sinus Zone 1. The purpose of this was to more closely evaluate anatomical links between dental disease and porous bone in the basal part of the sinus, with an aim of aiding the biological understanding of any statistical links that might be found.

Patterning in results is evaluated using inferential statistical tests applied to contingency tables (Zar, 1999: 486-502), with p values for significance set at 0.05. Observer error was quantified using Cohen's kappa (Bland, 2015: 317-322).

### 3. Results

The demographic composition of the study material is shown in Table 2.

Table 2. Age / sex balance of the study sample

Age (yrs)	Sex			Total
	Female	Male	Unsexed	
18-29	14	14	0	28
30-49	33	28	1	62
50+	18	25	0	43
Total	65	67	1	133

Observer error. For sinus Zone 1, recording was found to be without error (ie 100% agreement between original and repeat observations). For Zones 2 and 3, percentage agreement was 94.4% and 96.3% respectively; kappa (Bland, 2015: 317-322) values were 0.90 (95% CI=0.80-1.00) and 0.95 (95% CI=0.88-1.00) respectively.

Few zones (26/556) showed mixed lesions. In every instance, these comprised one clearly dominant type of lesion with a very minor additional element. For analytical purposes, these cases were therefore subsumed into the main scores according to their primary (dominant) element. Lesion frequency is summarised in Table 3.

Table 3. Cross-tabulation of lesion type versus location within sinus (left and right sides combined, observations on a total of 240 sinuses)

	Lesion type					Total
	Normal	Spicules	Lobules	Fine porosity	Coarse porosity	
Zone1 (sinus floor)	125 (53%)	72 (31%)	6 (3%)	13 (6%)	19 (8%)	235
Zone 2 (Medial wall)	99 (74%)	29 (22%)	3 (2%)	0	2 (2%)	133
Zone 3 (lateral wall)	118 (63%)	51 (27%)	5 (3%)	4 (2%)	10 (5%)	188
Total	342	152	14	17	31	556

There is no age or sex patterning in any of the lesions (Supplementary data). Bone changes of all types tend to show greater prevalences in Zone 1 than on the medial or lateral walls of the sinus (Table 3). In part this may be a taphonomic effect. Although at least 50% of a zone needed to be preserved in order for an observation to be entered, taphonomic damage to the (thinner) vertical sinus walls was generally greater than to the (thicker) sinus floor, so that loss of bony alterations would likely have been greater in the former. Spicules were by far the most commonly observed alteration in all zones.

For analytical purposes, the lesion types were henceforth collapsed into porous (combined coarse and fine porous lesions) versus spicules / lobules. The ratio of porous lesions: spicules / lobules was greater in Zone 1 (0.41) than elsewhere (0.06 in Zone 2, 0.25 in Zone 3). For statistical purposes, observations on left and right sinuses in a given individual cannot be considered independent observations, invalidating inferential statistical tests on sides combined. When split by side, the above patterning with regard to lesion type by zone failed to reach statistical significance (right side chi-square=3.86, 2df, p=0.14; left side chi-square=5.02, 2df, p=0.08).

Fourteen sinuses in 13 individuals showed oro-antral fistulae. Of these, five sinuses showed no bony deposits in Zone 1. One showed fine porosity, seven coarse porosity; one showed spicular bone.

If a sinus lesion type is associated with sinusitis then it should be more frequent above sockets showing the type of disease that may lead to sinusitis than a sinus lesion type that is not indicative of sinusitis. Results for the total of 110 sinuses that show lesions (see Table 3) are given in Table 4.



Spicules / lobules were evenly distributed supra-adjacent to diseased and non-diseased tooth rows. However, 26/32 (81%) of porous lesions in Zone 1 occurred supra-adjacent to diseased tooth rows. For both left and right sides the difference in the distribution of lesion types was statistically significant (Table 4).

Table 4. Frequency of porous and non-porous lesions in Zone 1 (sinus floor) above diseased and non-diseased tooth sockets

Left side

Sinus zone 1	Maxillary tooth sockets		Total
	Healthy	Diseased	
Spicules / lobules	23	16	39
Porous lesions	4	11*	15
Total	27	27	54

Chi sq=4.52, 1df, p=0.03.  $\phi$ =0.29

\*5 sockets periapical void, 2 sockets AMTL, 4 sockets both periapical void and AMTL.

Right side

Sinus zone 1	Maxillary tooth sockets		Total
	Healthy	Diseased	
Spicules / lobules	16	23	39
Porous lesions	2	15*	17
Total	18	38	56

Chi sq=4.65, 1df, p=0.03.  $\phi$ =0.29

\*6 sockets periapical void, 6 sockets AMTL, 3 sockets both periapical void and AMTL.

For definition of 'healthy' and 'diseased' tooth rows, see text.

A pattern resembling that observed in Zone 1 was also seen in lesions in Zone 3 (too few abnormalities were found in Zone 2 to establish a pattern). With sides combined, 13 of 14 sinuses showing porous lesions in Zone 3 also show diseased maxillary tooth rows; for spicules / lobules in Zone 3, 26 cases occur in the presence of healthy tooth rows in the same sinus, and in 29 cases they occur with diseased tooth rows. The association between lesion type in sinus Zone 3 and whether ipsilateral maxillary tooth sockets were diseased or healthy is significant for the right side (chi-square=4.61, 1df, p=0.03) but not for the left (chi-square = 2.34, 1df, p=0.12). In 11 of the cases of porous lesions where there is dental disease, the Zone 3 alterations are also accompanied by porous lesions in Zone 1 of the same sinus.

Because of the consistent statistical association between porous lesions in Zone 1 and subadjacent tooth row disease, a closer study was made of the location of porous lesions in Zone 1. Distinction was made between lesions that covered the general surface of Zone 1 and those that remained localised; for the latter it was noted whether it was possible to associate them with a specific subadjacent dental lesion.

The coarse porous lesions observed in the current study invariably covered the general surface of Zone 1. This was the case irrespective of the numbers of diseased subadjacent tooth positions, which ranged from zero to four. In 16 instances, the alterations consisted of deposits of porous bone upon the extant bone surface of the sinus floor. In the remaining three cases, this seemed likely but could not be conclusively confirmed because the deposits were so well-remodelled that their edges blended smoothly with the surrounding bone surface.

Turning to the finely porous lesions, in five instances they covered the general surface of Zone 1. In the remaining eight, they were focal. In seven of these, the lesions were confined supra-adjacent to the only one or two sockets in the subadjacent tooth row that were diseased (five periapical lesions and two cases of AMTL). In 11 instances, lesions were new bone deposits; in one case, the lesion comprised porosity of the extant surface with no gross evidence of new bone deposition, and one case was not clear.

#### 4. Discussion

The bony walls of the nasal cavity and sinuses are lined not with periosteum but with Schneiderian membrane (Whyte & Boeddinghaus, 2019). This has a tripartite histological structure, comprising a superficial epithelial layer, a *lamina propria* rich in blood vessels, and an inner layer adjacent to the bone surface. Histologically and cytologically, the inner layer resembles periosteum, and it appears similar in its osteogenic potential (Ren et al., 2022). The Schneiderian membrane possesses the form and function both of a mucosa and a periosteum. There is thus little *a priori* reason to believe that inflammation of the Schneiderian membrane in response to infection should give rise to bone that differs in its macroscopic morphology from that produced by inflammation in response to infection elsewhere in the skeleton. Our findings in the current study are generally consistent with this. The association between porous lesions in Zone 1 of the maxillary sinus and bony indicators of subadjacent dental disease of the type that biomedical studies show to be a factor in sinusitis, is consistent with the notion that these porous lesions are markers of maxillary sinusitis. However, we are aware that demonstrating a statistical link between alveolar disease and sinus lesions, despite the well-established potential for odontogenic infections to lead to sinus disease, does not of itself establish a causal link. In skeletal remains, temporal order of lesions, and hence causality, cannot in most instances be established. It should also be recalled that rhinogenic sinusitis may also potentially occur in Zone 1 regardless of the presence of dental disease. Because of this complexity, we also undertook detailed anatomical study of the morphology and location within Zone 1 of the porous lesions in an attempt to shed additional light on the relationship between the porous new bone in the sinus and subadjacent alveolar disease. The porous lesions we observed in Zone 1 of the maxillary sinus generally represent deposits of new bone upon the extant bone surface. Variation in macroscopic morphology of these deposits resembled that expected of bone showing varying degrees of remodelling, with the more finely porous lesions appearing less well remodelled than the more coarsely porous deposits (cf. Weston, 2008; Roberts, 2019). The observation that the coarsely porous lesions invariably covered the general surface of Zone 1, whereas the finely porous lesions were more often localised and generally lay supra-adjacent to a diseased tooth socket, is also consistent with the interpretation that the finely porous deposits often represented an earlier stage in the spread of infection to the sinus, when the disease was more localised. This is consistent with Bauer's (1943) original observations noting that odontogenic infection to the sinus from an infected root apex was via the network of capillaries extending to the local area immediately above, and with CT studies of odontogenic sinusitis that have visualised localised new bone deposits in the sinus floor above apices of diseased tooth sockets (Nunes et al., 2016).

In palaeopathology, it has been suggested (Lewis et al., 1995: 501-2) that irregular thickening of the maxillary sinus floor may simply be a response to maxillary molar loss rather than denoting sinusitis. This raises the possibility that the porous bone we found to be associated with dental disease might, at least when associated with AMTL, have been a response to tooth loss rather than being elicited by odontogenic infection. However, both theoretical and empirical evidence countermands this. Tooth loss would result in a decrease in functional forces transmitted to bone, so that bone resorption

rather than deposition is likely to be the predominant response in the adjacent maxillary sinus floor (Levi et al., 2017). Studies of the human maxillary sinus that focus in detail on changes in the floor of the antrum support this. Consensus suggests that, in the absence of sinusitis, when alteration is observed in the bone of the antral floor as a reaction to subadjacent tooth loss, it takes the form predominantly of resorption at this surface rather than deposition of bone (Wehrbein & Diedrich, 1992; Sharan & Madjar, 2008; Cavalcanti et al., 2018; cf. Velasco-Torres et al., 2017). Deposition of porous bone, as seen in our material, is unlikely to be a response to subadjacent tooth loss in the absence of sinusitis.

It could be suggested that, although the porous lesions represent a response within the sinus to infection from subadjacent dental disease, the spicules and lobules still indicate sinusitis, but they represent a response specifically to rhinogenic sinusitis, and that is why we found no link between them and dental disease. The microbiology of CRS of rhinogenic origin differs from that of odontogenic cause. Oral flora contribute to the latter (Akhlaghi et al., 2015; Psillas et al., 2021). Fungal organisms and allergy may play a part in rhinogenic CRS (Ferguson, 2014). Fungal sinusitis, like sinusitis of bacterial origin, may lead to thickening of the bony sinus walls (Jun et al., 2018). This bony thickening may occur with or without the bacterial co-infection which accompanies fungal sinusitis in the majority of cases (Wang et al., 2010; Jun et al., 2018). Given the morphological non-specificity of the bone formed in response to inflammation, there seems little reason to suppose that the morphology of bone deposited upon sinus walls is different in fungal sinusitis, even in the minority of instances where bacterial co-infection is absent. There seems no reason to suspect that the morphology of bone produced by the Schneiderian membrane in response to rhinogenic fungal sinusitis should differ from that elicited by sinusitis of odontogenic origin.

Both fungal and non-fungal rhinogenic sinusitis may produce calcifications within the sinus, unattached to the sinus walls (Momeni et al., 2007). These may be found surrounded by fungal mycelia or may be more peripherally located, within the thickened submucosal layer. These radio-opacities have been observed to be more frequent in fungal than in non-fungal sinusitis patients (51% vs 3%) and in the former they are more often located centrally in the sinus rather than peripherally (Yoon et al., 1999). The origin of intra-sinus radio-opacities is distinct from the thickening of the sinus walls that occurs via deposition of bone beneath the Schneiderian membrane – e.g. calcification may arise within the mycelial mass from deposition of calcium salts produced by fungal metabolism (Lenglinger et al., 1996). To our knowledge, free intra-sinus manifestations of sinus disease of the type described above (which may reach 6mm or more in diameter), have yet to be identified palaeopathologically. Given a favourable burial environment, they might potentially survive and form an additional source of information on sinusitis, perhaps helping us to enquire more closely as to its cause. In inhumation burials from earth-cut graves, maxillary sinuses are customarily filled with soil. During post-excavation processing of cranial remains, it may be worth collecting this soil and processing it to recover any within-sinus calcifications or ossifications that might be present.

In palaeopathology, the presence of an oro-antral fistula is sometimes taken as a ‘smoking gun’ indicating an odontogenic origin for maxillary sinus lesions (e.g. Merrett & Pfeiffer, 2000; Roberts, 2007; Sundmann & Kjellström, 2013a,b; Davies-Barrett et al., 2021a,b). However, in the current work, more than one-third of the sinuses showing fistulae had no further bony abnormalities in Zone 1, perhaps casting doubt on this. The status of the oro-antral fistula as an indicator of odontogenic infection of the sinus is further considered in a companion paper (Mays et al., in prep).

Unlike the porous lesions, the spicular / lobular alterations in Zone 1 showed no link with subadjacent alveolar disease of the type that may lead to sinusitis. This was despite a larger sample size than for the porous lesions. This finding forces consideration that the spicules / lobules (here largely represented by the former) arise by some other mechanism. Alterations resembling the lobules found here, and described elsewhere in the palaeopathology literature, have been documented to occur in the maxillary sinus due to cold shock (Ramakrishnan et al., 2010; Adelson & Kennedy, 2012; Schwartz et al., 2012). Pointed exostoses, apparently resembling the spicules seen by palaeopathologists in dry bones, have been identified, seemingly as anatomical variants, as incidental findings on imaging maxillary sinuses in patients (Ohba et al., 1993; Lana et al., 2011). But these are not likely explanations here. The former are rare and occur in patients who have undergone sinus surgery and who subsequently habitually irrigate with refrigerated nasal washes for extended periods (these lobules appear to be analogues to the auditory tori (Alexander et al., 2015) of cold-water swimmers). The latter are rare findings and are generally solitary.

The embryogenesis of the Schneiderian membrane means that it gives rise to a rather varied group of neoplasms, benign as well as malignant (Batsakis & Suarez, 2001). This raises the possibility that the spicules / lobules may represent some particular type of benign bone formation by the Schneiderian membrane. Whilst this might be a possibility, it would fail to explain why these are not seen elsewhere in locations covered by this membrane. For example, we found no evidence of any such bone deposits within the nasal cavity even when they were abundant within the maxillary sinus, and we are not aware of any such reports in the palaeopathology literature.

## **5. Conclusions**

Our results demonstrate a link between porous new bone formation within the maxillary sinus and evidence of types of lesions in subadjacent dentition that modern odontological literature links with sinusitis. This supports the idea that this type of sinus lesion indicates sinusitis. No such link was found for spicular / lobular lesions in the sinus, providing no support for the notion that these types of alterations represent sinusitis. Although there is a long tradition in palaeopathology in which the formation of spicules and lobules of bone on internal sinus walls are considered signs of sinusitis, the assumption that these specific types of bone formation are of inflammatory origin has lacked empirical evidential support. Our results, whilst not conclusive, raise the possibility that the assumption of a link between sinusitis and spicular / lobular bone deposits may need rethinking.

Further research is needed, along the lines of the present study, on populations exposed to different risk factors for sinus disease; work is currently in progress toward this end. We also aim at more detailed analyses of sinus and dental lesions so that more fine-grained associations between dental disease and bone changes in the sinus may emerge. However, our provisional recommendation, based on current results, is that spicules / lobules should be recorded and analysed separately from porous bone deposits in the maxillary sinuses in biocultural studies. It would be prudent to regard only the latter group of alterations as indications of sinusitis.

## **Acknowledgements**

A version of this paper was presented at the 2023 Palaeopathology Meeting in South America (PAMinSA), in Cochabamba, Bolivia. Thanks are due to delegates for useful discussion. We are grateful to the reviewers for their thoughtful comments on the manuscript.

## **References**

- Adelson RT, Kennedy DW. 2012. Paranasal sinus exostoses: possible correlation with cold temperature nasal irrigation after endoscopic sinus surgery. *Laryngoscope* 123: 24-27.
- Akhlaghi F, Esmaeelinejad M, Safai P. 2015. Etiologies and treatments of odontogenic maxillary sinusitis: a systematic review. *Iran Red Cresc Med J.* 17(2): e25536.
- Aksoy U, Orhan K. 2019. Association between odontogenic conditions and maxillary sinus mucosal thickening: a retrospective CBCT study. *Clin Oral Invest* 23: 123-131.
- Alexander V, Lau A, Beaumont E, Hope A. 2015. The effects of surfing behaviour on the development of external auditory canal exostoses. *Eur Arch Otorhinolaryngol* 272: 1643-1649.
- Allen H, Barnhouse NC, Chan BY. 2023. Periosteal pathologic conditions: imaging findings and pathophysiology. *RadioGraphics* 43(2): rg220120.
- Balta MG, Papathanasiou E, Blix IJ, Van Dyke TE. 2021. Host modulation and treatment of periodontal disease. *J Dent Res* 100(8): 798-809.
- Batsakis JG, Suarez P. 2001. Schneiderian papillomas and carcinomas: a review. *Adv Anat Pathol* 8(2): 53-64.
- Bauer WH. 1943. Maxillary sinusitis of dental origin. *Am J Orthod Oral Surg* 29: 133-151.
- Bernofsky K. 2010. Respiratory Health in the Past. A Bioarchaeological study of Chronic Maxillary Sinusitis and Rib Periostitis in the Iron Age to the Post-Mediaeval Period in Southern England. PhD Thesis, University of Durham.
- Bhandarkar ND, Mace JC, Smith TL. 2011. The impact of osteitis on disease severity measures and quality of life outcomes in chronic rhinosinusitis. *Int Forum Allergy Rhinol* 1: 372-378.
- Bisla S, Gupta A, Singh H, Sehrawat A, Shukla S. 2022. Evaluation of relationship between odontogenic infections and maxillary sinus changes: a cone beam computed tomography-based study. *J Oral Biol Craniofac Res* 12: 645-650.
- Bland, M. 2015. *An Introduction to Medical Statistics* (4<sup>th</sup> edn). Oxford University Press, Oxford.
- Boocock P, Roberts CA, Manchester K. 1995. Maxillary sinusitis in Medieval Chichester, England. *Am J Phys Anthropol* 98: 486-495.
- Boyd DA. 2020. Respiratory stress at the periphery of Industrial-era London: insight from parishes within and outside the city. In: Betsinger TK, DeWitte SN (Eds) *The Bioarchaeology of Urbanisation*. Springer, Cham. pp. 379-402.
- Brothwell DR, Browne S. 1994. Pathology. In Lilley, J.M., Stroud, G., Brothwell, D.R., Williamson, M.H. *The Jewish Burial Ground at Jewbury. The Archaeology of York* 12/3. York Archaeological Trust for Excavation and Research, York. pp. 457-494.
- Buchner H-J., Lessel W. 1978. Über Knochenveränderungen bei chronischen odontogenen kieferhohlenentzündungen. *Stomatol DDR* 28: 883-887.
- Casna M, Schrader SA. 2022. Urban beings: a bioarchaeological approach to socioeconomic status, cribra orbitalia, porotic hyperostosis, linear enamel hypoplasia, and sinusitis in the early-Modern northern Low Countries (A.D. 1626-1850). *Bioarchaeol Int* 4: 217-232.
- Casna M, Burrell CL, Schats R, Hoogland MLP, Schrader SA. 2021. Urbanisation and respiratory stress in the Northern Low Countries: a comparative study of chronic maxillary sinusitis in two early modern sites from the Netherlands (AD 1626-1866). *Int J Osteoarchaeol* 31: 891-901.
- Casna M, Schats R, Hoogland MLP, Schrader SA. 2023. A distant city: assessing the impact of Dutch socioeconomic developments on urban and rural health using respiratory disease as a proxy. *Int J Paleopathol* 42: 34-45.
- Cavalcanti MC, Guirado TE, Sapata VM, Costa C, Pannuti CM, Jung RE, César-Neto JB. 2018. Maxillary sinus floor pneumatisation and alveolar ridge resorption after tooth loss: a cross-sectional study. *Braz Oral Res* 32: e64.
- Clarke NG, Hirsch RS. 1991. Physiological, pulpal and periodontal factors influencing alveolar bone. In: Kelley MA, Larsen CS (Eds) *Advances in Dental Anthropology*. Wiley-Liss, Chichester. pp. 241-266.
- Collins C. 2018. *The Palaeopathology of Maxillary Sinusitis, Otitis Media and Mastoiditis in Medieval Iceland*. PhD Thesis, University of Reading.

- Curi FR, Pelegrine RA, Nascimento MdoCC, Montiero JCC, Junqueira JLC, Panzarella FK. 2020. Odontogenic infection as a predisposing factor for pathologic disorder development in the maxillary sinus. *Oral Dis* 26: 1727-1735.
- Cybulski JS. 1988. Skeletons in the walls of old Quebec. *Northeast Hist Archaeol* 17: 61-84.
- Darveau RP. 2010. Periodontitis: a polymicrobial disruption of host homeostasis. *Nature Rev Microbiol* 8: 481-490.
- Davies-Barrett AM, Roberts CA, Antoine D. 2021a. Time to be nosy: evaluating the impact of environmental and sociocultural changes on maxillary sinusitis in the Middle Nile Valley (Neolithic to Medieval periods). *Int J Paleopathol* 34: 182-196.
- Davies-Barrett AM, Owens LS, Eeckhout PA. 2021b. Paleopathology of the Ychsma: evidence of respiratory disease during the Late Intermediate period (AD 1000-1476) at the Central Coastal site of Pachacamac, Peru. *Int J Paleopathol* 34: 63-75.
- Digangi EA, Sirianni JE. 2017. Maxillary sinus infection in a 19<sup>th</sup> century almshouse skeletal sample. *Int J Osteoarchaeol* 27: 155-166.
- Dumitrescu A, Martu M-A, Nemtoi A, Sirghe A, Chelaru L, Tatarciuc D, Dumitrescu A-M, Haba D. 2021. Association between cone-beam computed tomography and histological and immunohistochemical features in periapical lesions correlated with thickened maxillary sinus mucosa. *Medicina* 57: 840.
- Ferguson M. 2014. Rhinosinusitis in oral medicine and dentistry. *Austral Dent J* 59: 289-295.
- Fokkens WJ, Lund VJ Hopkins C, Hellings PW, Kern R, Reitsma S. et al. 2020. European Position Paper on Rhinosinusitis and Nasal Polyps 2020. *Rhinol Suppl.* 29: 1-464.
- Georgalas C, Videler W, Freling N, Fokkens W. 2010. Global osteitis scoring scale and chronic rhinosinusitis: a marker of revision surgery. *Clin Otolaryngol* 35: 455-461.
- Gregg JB, Gregg PS. 1987. *Dry Bones: Dakota Territory Reflected*. Sioux Printing, Sioux Falls.
- Hajishengallis G, Chavakis T, Lambris JD. 2020. Current understanding of periodontal disease pathogenesis and targets for host-modulation therapy. *Periodontol* 2000 84(1): 14-34.
- Hauman, CHJ, Chandler NP, Tong DC. 2002. Endodontic implications of the maxillary sinus: a review. *Int Endod J.* 35: 127-141.
- Huang Y-T, Hu, S-W, Huang J-Y, Chang Y-C. 2021. Assessment of the relation between maxillary sinus membrane thickening and adjacent teeth health by cone-beam computed tomography. *J Dent Sci* 16: 275-279.
- Jun YJ, Shin JM, Lee JY, Baek BJ. 2018. Bony changes in a unilateral maxillary sinus fungal ball. *J Craniofac Surg* 29:(1): e44.
- Kerr NW. 1998. Dental pain and suffering prior to the advent of modern dentistry. *Br Dent J* 184: 397-399.
- Kim HY, Dhong H-J, Lee HJ, Chung H-J, Yim YJ, Oh J-W, Chung S-K, Kim HJ. 2006. Hyperostosis may affect prognosis after primary endoscopic sinus surgery for chronic rhinosinusitis. *Otolaryngol Head Neck Surg* 135: 94-99.
- Krenz-Niedbala M, Łukasik S. 2020. Urban-rural differences in respiratory tract infections in Mediaeval and Early Modern Polish subadult samples. In: Betsinger TK, DeWitte SN (Eds) *The Bioarchaeology of Urbanisation*. Springer, Cham. pp. 245-272.
- Kuligowski P, Jaroń A, Preuss O, Gabrysz-Trybek E, Bładowska J, Trybek G. 2021. Associations between odontogenic and maxillary sinus conditions: a retrospective cone-beam computed tomographic study. *J Clin Med* 10: 2849.
- Lana JP, Carneiro PMR, Machado VdeC, de Souza PEA, Manzi FR, Horta MCR. 2011. Anatomic variations and lesions of the maxillary sinus detected in cone beam computed tomography for dental implants. *Clin Oral Implants Res* 23: 1398-1403.
- Larsen CS. 2015. *Bioarchaeology. Interpreting Behaviour From the Human Skeleton* (2<sup>nd</sup> edn). Cambridge University Press, Cambridge.

- Lathiya VN, Kolte AP, Kolte RA, Mody DR. 2019. Analysis of association between periodontal disease and thickness of maxillary sinus mucosa using cone-beam computed tomography – a retrospective study. *Saudi Dent J* 31: 228-235.
- Lechien JR, Filleul O, de Araujo PC, Hseih JW, Chantrain G, Saussez S. 2014. Chronic maxillary rhinosinusitis of dental origin: a systematic review of 674 patient cases. *Int J Otolaryngol* 2014: 465173.
- Lee MJ, Siek TJ, Hirst CS. 2024. Chronic maxillary sinusitis in palaeopathology: a review of methods. *Int J Paleopathol* 44: 51-64.
- Lee JT, Kennedy DW, Palmer JN, Feldman M, Chiu JG. 2006. The incidence of concurrent osteitis in patients with chronic rhinosinusitis: a clinicopathological study. *Am J Rhinol* 20: 278-282.
- Leland EM, Vohra V, Seal SM, Zhang Z, Ramanathan M. 2022. Environmental air pollution and chronic rhinosinusitis: a systematic review. *Laryngoscope Invest Otolaryngol* 7: 349-360.
- Lenglinger FK, Krennmair G, Müller-Schelken H, Artmann W. 1996. Radiodense concretions in maxillary sinus aspergillosis: pathogenesis and the role of CT densitometry. *Eur Radiol* 6: 375-379.
- Levi I, Halperin-Sternfeld M, Horowitz J, Zigdon-Giladi H, Machtei E. 2017. Dimensional changes of the maxillary sinus following tooth extraction in the posterior maxilla with and without socket preservation. *Clin Implant Dent Relat Res* 19: 952-958.
- Lewis M, Roberts CA, Manchester K. 1995. Comparative study of the prevalence of maxillary sinusitis in later Medieval urban and rural populations from northern England. *Am J Phys Anthropol* 98: 497-506.
- Liebe-Harkort C. 2012. Cribra orbitalia, sinusitis and linear enamel hypoplasia in Swedish Roman Iron Age adults and subadults. *Int J Osteoarchaeol* 22: 387-397.
- Mafee MF, Farid N, Lim WY. 2014. Imaging of the paranasal sinuses: plain-film radiography, computed tomography, and magnetic resonance imaging. In: Chang CC, Incaudo GA, Gershwin ME (Eds) *Diseases of the Sinuses, A comprehensive Textbook of Diagnosis and Treatment* (2<sup>nd</sup> edn). Springer, New York. pp. 295-322.
- Magalhães BM. 2018. When Breathing is a Burden. *Sinonasal Variations and Diseases Affecting the Human Skull in Three Portuguese Identified Osteological Collections (19th-20th Centuries)*. PhD Thesis, University of Coimbra.
- Magalhães BM, Santos AL, Mays SA. 2017. Does the Presence of Nasal Variations Predispose to Maxillary Sinusitis? Presentation at the XIX Congreso Nacional e Internacional de Paleopatología, Alicante, Spain, November 2017.
- Mahoney-Swales D. 2018. A biocultural analysis of mortuary practices in the later Anglo-Saxon to Anglo-Norman Black Gate cemetery, Newcastle-Upon-Tyne, England. *Int J Osteoarchaeol* 29: 198-219.
- Martu C, Martu M-A, Maftai G-A, Diaconu-Popa DA, Radulescu L. 2022. Odontogenic sinusitis: from diagnosis to treatment possibilities – a narrative review of recent data. *Diagnostics* 2022(12): 1600.
- Mays S. 2007. The human remains. In: Mays S, Harding C, Heighway C. *Wharram, A Study of Settlement on the Yorkshire Wolds XI: The Churchyard*. York University Archaeological Publications 13, University of York, York. pp. 77-192.
- Mays S, Mavrogordato M, Lambert J, Sofaer J. 2014. The prevalence and health implications of concha bullosa in a population from Mediaeval England. *Int J Osteoarchaeol* 24: 614-622.
- Merrett DC, Pfeiffer S. 2000. Maxillary sinusitis as an indicator of respiratory health in past populations. *Am J Phys Anthropol* 111: 301-318.
- Momeni AK, Roberts CC, Chew FS. 2007. Imaging of chronic and exotic sinonasal disease: review. *AJR* 189: S35-S45.
- Nunes CABCM, Guedes OA, Alencar AHG, Peters OA, Estrela CRA, Estrela C. 2016. Evaluation of periapical lesions, and their association with maxillary sinus abnormalities on cone-beam computed tomographic images. *J Endod* 42: 42-46.
- Ogden A. 2008. Advances in the palaeopathology of teeth and jaws. In: Pinhasi R, Mays S (Eds) *Advances in Human Palaeopathology*. Wiley, Chichester. pp. 283-307.

- Ohba T, Langlais RP, Langland OE, 1993. Antral exostosis in panoramic radiographs. *Oral Surg Oral Med Oral Pathol* 76: 530-533.
- Ortner DJ. 2008. Differential diagnosis of skeletal lesions in infectious disease. In Pinhasi R, Mays S (eds) *Advances in Human Palaeopathology*. Wiley, Chichester. pp. 191-214.
- Panhuyzen RGAM, Coenen V, Bruintjes TD. 1997. Chronic maxillary sinusitis in Medieval Maastricht. *Int J Osteoarchaeol* 7: 610-614.
- Psillas G, Papaioannou D, Petsali S, Dimas GG, Constantinidis J. 2021. Odontogenic maxillary sinusitis: a comprehensive review. *J Dent Sci* 16: 474-481.
- Ramakrishnan JB, Pirron JA, Perepletchikov A, Ferguson BJ. 2010. Exostoses of the paranasal sinuses. *Laryngoscope* 120: 2532-2534.
- Ren J, Geng N, Xia Y, Zhou Y, Tan J, Peng W, Chen S. 2022. A comparative study of the morphology and molecular biology between the Schneiderian membrane and the palatine mucoperiosteum. *Tissue Cell* 79: 101948.
- Ren S, Zhao H, Liu J, Wang Q, Pan Y. 2015. Significance of maxillary sinus mucosal thickening in patients with periodontal disease. *Int Dent J* 65: 303-310.
- Resnick D. 1995. *Diagnosis of Bone and Joint Disorders* (3<sup>rd</sup> edition). WB Saunders, Philadelphia.
- Riccomi G, Casaccia J, Minozzi S, Felici C, Compana S, Giuffra V. 2021. Maxillary sinusitis as a respiratory health indicator: a bioarchaeological investigation into Medieval central Italy. *Int J Paleopathol* 35: 40-48.
- Roberts CA. 2007. A bioarchaeological study of maxillary sinusitis. *Am J Phys Anthropol* 133: 792-807.
- Roberts CA. 2019. Infectious disease: introduction, periostosis, periostitis, osteomyelitis and septic arthritis. In Buikstra J (Ed) *Ortner's Identification of Pathological Conditions in Human Skeletal Remains* (3<sup>rd</sup> edn). Academic Press, London. pp. 285-319.
- Roney JG. 1959. Palaeopathology of a California archaeological site. *Bull Hist Med* 33(2): 97-109.
- Sakir M, Yalcinkaya SE. 2020. Associations between periapical health of maxillary molars and mucosal thickening of maxillary sinuses in cone-beam computed tomographic images: a retrospective study. *J Endod* 46: 397-403.
- Schwartz KM, Eckel LJ, Black DF, Lehman VT, Diehn FE, Hunt CH, Lindell EP. 2012. Irrigation nose: CT findings of paranasal sinus exostoses. *Open Neurosurg J* 6: 90-91.
- Shanbhag S, Karnik P, Shirke P, Shanbhag V. 2013. Association between periapical lesions and maxillary sinus mucosal thickening: a retrospective cone beam computed tomographic study. *J Endod* 39: 853-857.
- Sharan A, Madjar D. 2008. Maxillary sinus pneumatization following extractions: a radiographic study. *Int J Oral Maxillofac Implants* 01/2008: 48-56.
- Sheikhi M, Pozvi NJ, Khorrani L. 2014. Using cone beam computed tomography to detect the relationship between the periodontal bone loss and mucosal thickening of the maxillary sinus. *Dent Res J* 11(4): 495-501.
- Snidvongs K, McLachlan R, Chin D, Pratt E, Sacks R, Earls P, Harvey RJ. 2012. Osteitic bone: a surrogate marker of eosinophilia in chronic rhinosinusitis. *Rhinol* 50: 299-305.
- Snidvongs K, McLachlan R, Sacks R, Earls P, Harvey RJ. 2013. Correlation of the Kennedy Osteitis Score to clinico-histologic features of chronic rhinosinusitis. *Int Forum Allergy Rhinol* 3: 369-375.
- Sundman EA, Kjellström A. 2013a. Chronic maxillary sinusitis in Medieval Sigtuna, Sweden: a study of sinus health and effects on bone preservation. *Int J Osteoarchaeol* 23: 447-458.
- Sundman EA, Kjellström A. 2013b. Signs of sinusitis in times of urbanisation in Viking Age – Early Medieval Sweden. *J Archaeol Sci* 40: 4457-4465.
- Suzuki T, Dodo Y, Nishimoto T. 1983. On the so-called "isolated bone fragment" in the maxillary sinus found in Jomon skulls from Hokkaido. *J Anthropol Soc Nippon* 155-164.
- Telmesani LM, Al-Shawarby M. 2010. Osteitis in chronic rhinosinusitis with nasal polyps; a comparative study between primary and recurrent cases. *Eur Arch Otorhinolaryngol* 267: 721-724.



- Teul I, Lorkowski J, Lorkiewicz W, Nowakowski D. 2013. Sinusitis in people living in the Middle Ages. In Pokorski M. (Ed) *Neurobiology of Respiration*. Springer, New York. pp. 133-138.
- Tovi F, Benharroch D, Gatot A, Hertzanu Y. 1992. Osteoblastic osteitis of the maxillary sinus. *Laryngoscope* 102: 426-430.
- Troeltzsch M, Pache C, Troeltzsch M, Kaeppler G, Ehrenfeld M, Otto S, Probst F. 2015. Etiology and clinical characteristics of symptomatic unilateral maxillary sinusitis: a review of 174 cases. *J Cranio-Maxillo-Facial Surg* 43: 1522-1529.
- Velasco-Torres M, Padiál-Molina M, Avila-Ortiz G, García-Delgado R, O'Valle F, Catena A, Galindo-Moreno P. 2017. Maxillary sinus dimensions decrease as age and tooth loss increase. *Implant Dent* 26(2): 288-295.
- Vidal F, Coutinho TM, Ferreira DdeC, de Souza RC, Gonçalves LS. 2017. Odontogenic sinusitis: a comprehensive review. *Acta Odontol Scand* 75: 623-633.
- Wang JH, Lree B-J, Jang YJ. 2010. Bacterial coinfection and antimicrobial resistance in patients with paranasal sinus fungus balls. *Ann Otol Rhinol Laryngol* 119(6): 406-411.
- Wehrbein H, Diedrich P. 1992. Die Fortschreitende Pneumatisation der basalen Kieferhöhle nach Extraktion und Lüchenschluss. *Fortschr Kieferorthop* 53: 77-83.
- Wells C. 1977. Disease of the maxillary sinus in antiquity. *Med Biol Illustration* 27: 173-178.
- Wenaden AET, Szyszko TA, Saifuddin A. 2005. imaging of periosteal reactions associated with focal lesions of bone. *Clin Radiol* 60: 439-456.
- Weston DA. 2008. Investigating the specificity of periosteal reactions in pathology museum specimens. *Am J Phys Anthropol* 137: 48-59.
- Whyte A, Boeddinghaus R. 2019. The maxillary sinus: physiology, development and imaging anatomy. *Dentomaxillofacial Radiol* 48: 20190205.
- Yoon JH, Na DG, Byun HS, Koh YH, Chung SK, Dong H-J. 1999. Calcification in chronic maxillary sinusitis: comparison of CT findings with histopathologic results. *Am J Neuroradiol* 20: 571-574.
- Zar J. 1999. *Biostatistical Analysis* (4<sup>th</sup> Edn). Prentice Hall. Upper Saddle River.

#### Figure captions

Figure 1. Left maxillary sinus, showing zonal recording system. A. Zone 1 (sinus floor). B. Zone 2 (medial wall). C. Zone 3 (lateral wall).

Figure 2. Types of bone alteration in the maxillary sinus. (a) Normal (b) Spicules (c) Lobules (d) Fine porosity (e) Coarse porosity.

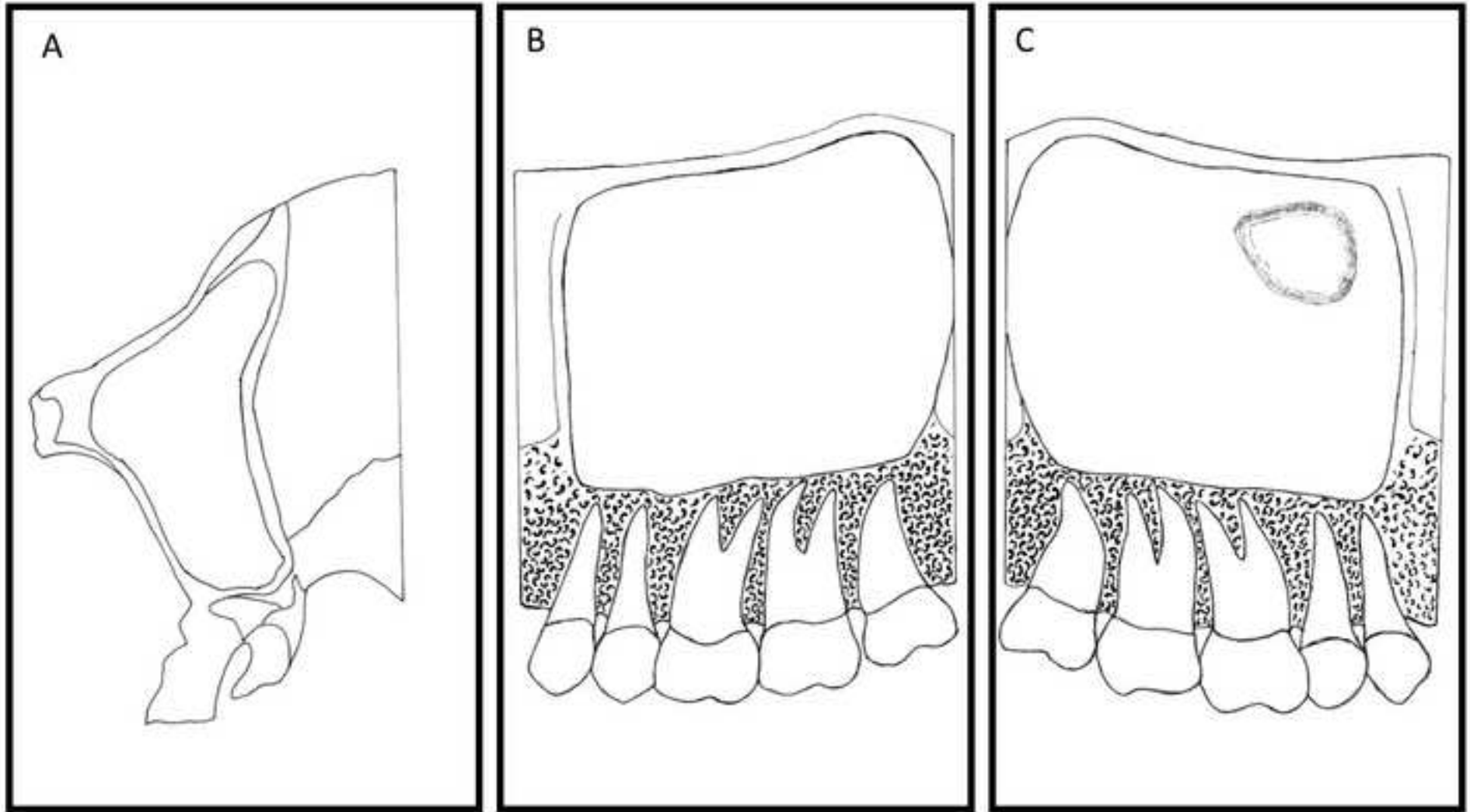




Figure 2b







